



Public Health
England



NHS Bowel Cancer Screening Programme

Guidance on reporting lesions

Public Health England leads the NHS Screening Programmes

About Public Health England

Public Health England (PHE) exists to protect and improve the nation's health and wellbeing, and reduce health inequalities. We do this through world-leading science, knowledge

and intelligence, advocacy, partnerships and the delivery of specialist public health services. We are an executive agency of the Department of Health, and a distinct delivery organisation with operational autonomy to advise and support government, local authorities and the NHS in a professionally independent manner.

Public Health England, Wellington House, 133-155 Waterloo Road, London SE1 8UG

Tel: 020 7654 8000 www.gov.uk/phe

Twitter: @PHE_uk Facebook: www.facebook.com/PublicHealthEngland

About PHE screening

Screening identifies apparently healthy people who may be at increased risk of a disease or condition, enabling earlier treatment or better informed decisions. National population screening programmes are implemented in the NHS on the advice of the UK National Screening Committee (UK NSC), which makes independent, evidence-based recommendations to ministers in the four UK countries. The Screening Quality Assurance Service ensures programmes are safe and effective by checking that national standards are met. PHE leads the NHS Screening Programmes and hosts the UK NSC secretariat.

PHE Screening, Floor 2, Zone B, Skipton House, 80 London Road, London SE1 6LH

www.gov.uk/topic/population-screening-programmes

Twitter: @PHE_Screening Blog: phescreening.blog.gov.uk

Prepared by: [this line can be deleted if not required]

For queries relating to this document, please contact: phe.screeninghelpdesk@nhs.net

© Crown copyright 2017

You may re-use this information (excluding logos) free of charge in any format or medium, under the terms of the Open Government Licence v3.0. To view this licence, visit [OGL](https://www.nationalarchives.gov.uk/ogp/) or email psi@nationalarchives.gsi.gov.uk. Where we have identified any third party copyright information you will need to obtain permission from the copyright holders concerned.

Published January 2018

PHE publications

gateway number: 201XXXX

PHE supports the UN

Sustainable Development Goals



Contents

About Public Health England	2
About PHE screening	2
Preface	4
1. Executive summary	6
2. Introduction	7
3. Standards	8
3.1 Reporting requirements	8
3.2 Standards relating to BCSP pathology	9
3.3 Standards relating to colorectal cancer pathology	10
3.4 Endoscopy requirements	10
4. Specimen handling	11
4.1 Measurement	11
4.2 Sectioning	11
4.3 Margins	12
5. Reporting non-invasive lesions	12
5.1 Data	12
5.2 Classical adenomas	13
5.3 Serrated lesions	26
5.4 Inflammatory polyps	31
6. Reporting invasive neoplasia	32
6.1 Definition of invasion	32
6.2 Reporting of diagnostic biopsy specimens	32
6.3 Stage pT1 adenocarcinoma	33
6.4 Histological tumour type	34
6.5 Histological differentiation	34
6.6 Extent of local invasion	35
6.7 Lymphatic, venous and perineural invasion	36
6.8 Presence of a precursor lesion	37
6.9 Margin assessment	37
6.10 Tumour budding	40
References	42
Appendix 1 Bowel Cancer Screening System (BCSS) polyp dataset (2017)	47
Appendix 2 Recommended SNOMED codes	48
Appendix 3 TNM 8 classification of colorectal tumours	51

Preface

This guidance is produced in collaboration with the pathology committees of the United Kingdom and Ireland Bowel Cancer Screening Programmes.

Writing committee:

Dr Maurice B. Loughrey, Royal Victoria Hospital, Belfast Trust, Queen's University Belfast, Belfast, Northern Ireland

Dr Adrian C. Bateman, University Hospital Southampton NHS Foundation Trust, Southampton, England

Professor Neil A. Shepherd, Gloucestershire Cellular Pathology Laboratory, Cheltenham, England

Professor Philip Quirke, Leeds Teaching Hospitals NHS Trust and Leeds University, Leeds, England

Contributions by:

Lead Pathology Irish Bowel Cancer Screening Programme

Professor Kieran Sheahan, St Vincent's Hospital, Dublin, Ireland

Lead Pathology Northern Ireland Bowel Cancer Screening Programme

Dr Maurice B. Loughrey, Royal Victoria Hospital, Belfast Trust, Queen's University Belfast, Belfast, Northern Ireland

Lead Pathology Scotland Bowel Cancer Screening Programme

Professor Frank Carey, Ninewells Hospital, Dundee, Scotland

Lead Pathology Welsh Bowel Cancer Screening Programme

Dr Namor Williams, Abertawe Bro Morgannwg University Local Health Board, Wales
Professor Geraint Williams, University Hospital of Wales, Cardiff (2006-11)

English Pathology Bowel Cancer Screening Committee 2006 – present, in alphabetical order

Dr Adrian C. Bateman, University Hospital Southampton NHS Foundation Trust, Southampton

Dr Ann Buxton, Harrogate and District NHS Foundation Trust, Harrogate (2014-16)

Dr Philip DaCosta, Airedale Hospital NHS Foundation Trust, Keighley (2006-13)

Dr James Henry, Gateshead Health NHS Foundation Trust, Gateshead

Dr Nic Mapstone, Manchester Royal Infirmary, Manchester

Professor Philip Quirke, Leeds Teaching Hospitals and Leeds University, Leeds

Dr Manuel Rodriguez-Justo, University College Hospital NHS Foundation Trust, London

Dr Scott Sanders, South Warwickshire, NHS Foundation Trust, Warwick (2006-2016)

Professor John Schofield, Maidstone and Tunbridge Wells NHS Trust, Maidstone

Professor Neil A. Shepherd, Gloucestershire Cellular Pathology Laboratory,
Cheltenham

Professor Kevin West, Leicester Royal Infirmary, Leicester

Public Health England, Screening Division

John Davy (in memoriam) Programme Manager (2015-2017), NHS Bowel Cancer
Screening Programme

Billie Moores, National Quality Assurance Lead, NHS Bowel Cancer Screening
Programme

These guidelines have been endorsed by the:

Royal College of Pathologists

Association for Coloproctology of Great Britain and Ireland

British Society of Gastroenterology – Pathology Section

British Division of the International Academy of Pathology

1. Executive summary

This document is NHS Bowel Cancer Screening Programme (BCSP) guidance and updates the original 2007 version (NHS BCSP Publication No. 1). It is effective from 1 January 2018, and aims to support consistent practice and data collection as well as developing the evidence base for future recommendations regarding routine practice.

The NHS BCSP Pathology Committee engages with pathologists across the United Kingdom (UK) and Ireland. The standards mentioned within this document refer specifically to the English programme. Different arrangements may apply elsewhere but most aspects of this guidance will be common to all.

These guidelines are consistent with the guidance and dataset produced by the Royal College of Pathologists (UK) (RCPath) for reporting colorectal cancer (CRC) (2). They are also consistent with the quality assurance guidelines commissioned by the European Union in 2010 (3).

The main updates to the 2007 version of this publication are:

- elaboration of standards applicable to pathologists reporting BCSP specimens (section 3.1)
- expectations required of endoscopists submitting BCSP specimens for histology (section 3.4)
- careful consideration of adenoma sizing, as this is important for colonoscopic surveillance pathways (section 5.2.2)
- elaboration of descriptors and minimum diagnostic criteria for villousness, in an attempt to improve reproducibility (section 5.2.3)
- assessment of polypectomy margin – distinguishing margin involvement by dysplasia from incomplete excision of adenocarcinoma (section 5.2.5)
- detailed discussion of epithelial misplacement within adenomas versus adenocarcinoma (section 5.2.6)
- update in terminology to be applied to serrated lesions (section 5.3)
- minimum criteria for diagnosing adenocarcinoma on endoscopic biopsy specimens (section 6.2)
- reporting of stage pT1 CRC in line with recommendations in the RCPath guidance (2), to include depth and width of invasion (in mm) and separate assessment of lymphatic, neural and venous invasion (section 6.3)
- reference to National Institute for Health and Care Excellence (NICE) recommendation on performing mismatch repair (MMR) immunohistochemistry or microsatellite instability (MSI) testing in all cases of colorectal cancer (4) (section 6.5)

Changes as detailed in the RCPATH guidance (2) to the surgical resection dataset proforma for the move from TNM5 to TNM8 (Appendix 3) are:

- changes to T, N and M staging categories
- the Dukes and Bussey classification of CRC staging is no longer to be reported, as it is not compatible with TNM 8 staging
- the number of tumour deposits (use the precise number up to 5, or use '>5') should be recorded in node negative cases only (stage pN1c in TNM 8)
- depth of venous invasion is now recorded as extramural or intramural (comprising submucosal and intramuscular)
- the presence (L1) or absence (L0) of lymphatic (small vessel) infiltration should be recorded, with an indication of greatest depth of invasion (extramural or intramural)
- the presence (Pn1) or absence (Pn0) of perineural infiltration should be recorded, with an indication of greatest depth of invasion (extramural or intramural)
- assessment of tumour regression following preoperative therapy has been modified slightly and a tumour regression score (0–3) added
- the section describing separate abnormalities in the specimen (aside from the tumour) has been simplified
- recording of additional immunohistochemical and molecular data

2. Introduction

The aim of this document is to help pathologists report specimens which derive from BCSP practice. The vast majority of such specimens will be endoscopic in origin, either polypectomies or mucosal biopsies. A minority will be other forms of local excision specimen, such as endoscopic mucosal resection (EMR), or surgical resection specimens for colorectal neoplasms deemed unsuitable for local resection.

Most BCSP colonoscopy specimens are diagnosed as adenomatous polyps, with adenocarcinoma and inflammatory conditions each comprising fewer than 10% of specimens in the BCSP setting. Flexible sigmoidoscopy screening generates fewer cancers, fewer large adenomas and more hyperplastic polyps due to the anatomical segment examined in this screening method. Within screen-detected CRCs, a higher proportion are early stage (stage pT1) compared to symptomatic CRCs, and frequently these can be treated by polypectomy or a form of local excision only.

Given this typical distribution of BCSP specimens, the emphasis within this guidance is on reporting non-malignant polyps and on polypectomy or other local excision specimens which contain adenocarcinoma. It is beyond the scope of this document to

discuss reporting of surgical resection specimens or colorectal inflammatory conditions in detail. You are referred to the guidance and dataset produced by the RCPATH, major gastrointestinal pathology textbooks and elsewhere in this regard (2, 5, 6).

Standardisation of pathology reporting is emphasised. This includes which data items are reported and the approach to, and nomenclature used for, each data item. This guidance aims to standardise BCSP pathology reporting further, and to facilitate regional, national and international comparisons for audit and research purposes. We strongly encourage the use of standardised agreed datasets and electronic reporting systems, to aid collation of data by appropriate registries.

3. Standards

3.1 Reporting requirements

Pathologists who wish to start reporting BCSP (including BowelScope) cases should:

- inform their Regional Screening Quality Assurance Service (SQAS) to ensure they receive relevant quality assurance (QA) information
- typically be in a substantive consultant post and this will be confirmed by the regional pathology clinical advisor via the SQAS
- register for the national BCSP external quality assurance (EQA) scheme and participate in the next available round

During a QA visit, the regional pathology clinical advisor will check that all reporting pathologists:

- participate in the national EQA scheme, defined as participation in two of the last three circulations
- have attended an educational event, relevant to their screening work, in at least one of the past three years.

Pathologists who do not fulfil these requirements should not report BCSP cases. SQAS will hold a list of BCSP pathologists whilst these requirements are embedded into routine practice.

3.2 Standards relating to BCSP pathology

1. To report BCSP cases, pathologists must fulfil the criteria specified in section 3.1. In addition, they should participate in local QA visits and audit their own reporting practice alongside colleagues.
2. Pathologists must complete either the screening programme proforma or its computerised version for each BCSP case and each polyp reported. These should be returned to the screening centre administrator for pathology data to be entered onto the central bowel cancer screening system (BCSS). A copy of the latest version of the BCSP proforma is provided in Appendix 1. Pathologists may also wish to provide a free text report directly to the clinician.
3. Turnaround time of pathology reports should allow patients who have had lesions removed at endoscopy to be managed appropriately and given a timely appointment to be seen at a follow-up clinic if required. Current QA standards relating to turnaround times should be adhered to, with day zero being receipt of sample in the laboratory and the end point being the day the report is authorised. Interim reports are encouraged if cases are referred for second opinions.
4. Between 3% and 10% of adenomas reported in the setting of a faecal occult blood (FOB)/faecal immunochemical test (FIT) based screening programme are expected to be classified as having high grade dysplasia (section 5.2.4). Between 1% and 5% of adenomas reported in the setting of flexible sigmoidoscopy-based screening (such as bowel scope screening) are expected to be classified as having high grade dysplasia.
5. Appropriate SNOMED codes should be applied to all cases (Appendix 2).
6. Cancers should be reported according to the latest Royal College of Pathologists (UK) and BCSP guidelines.

Double reporting of all pT1 cancers is required to minimise overdiagnosis of adenocarcinoma. Both reporting pathologists should be BCSP registered and named on the pathology report. If there is any doubt about a diagnosis of cancer, then referral is required for a further opinion. It is recommended that a local opinion is sought first with a further regional opinion or opinion from the national 'Expert Board' should the diagnosis still be in doubt.

These standards should be monitored by regular departmental audit, for all BCSP pathologists involved. Other audits which may be informative could address measuring size of adenomas and interobserver variation in frequencies of classifying adenomas as tubular or villous/tubulovillous.

3.3 Standards relating to colorectal cancer pathology

These relate to the RCPATH dataset (2).

It is recommended that multidisciplinary teams and/or pathology departments audit their CRC resection pathology reports at regular intervals. Three standards are recommended, and should be audited for each BCSP pathologist. These should be evaluated on a series of at least 50 resection specimens from symptomatic patients (not screen-detected cancers) who have not undergone pre-operative therapy.

1. The number of lymph nodes examined should be as high as possible with at least a median of 12 per case and many centres reporting a median of 15-25 per case.
2. The frequency of serosal involvement should be at least 20% for colonic cancers.
3. The frequency of venous invasion, including intramural (submucosal and intramuscular) and extramural, should be at least 30%.

It is also worthwhile auditing frequencies of reporting of important features within stage pT1 CRC polypectomy specimens, such as lymphatic invasion, venous invasion and poor differentiation.

3.4 Endoscopy requirements

It is essential that the histopathology request form accompanying any BCSP specimen includes all the relevant information to allow thorough and accurate pathology reporting. The responsible endoscopist should include:

- patient demographic details, including NHS/Health and Care number or other unique identifier
- date of endoscopy
- relevant clinical information
- endoscopic findings

The form should clearly indicate, by means of a suitable label or stamp, that the specimen has resulted from BCSP endoscopy and must therefore be reported by a BCSP pathologist. Bowel scope specimens should be clearly identified as such.

A copy of the endoscopy report should be submitted with the request form, and if possible, accompanied by an endoscopic photographs of any lesions identified. As a minimum, the request form should specify:

- the precise number and respective sites of any polyps submitted for histology
- any clinical suspicion of malignancy at endoscopy
- endoscopic polyp sizes

Each individual polyp should be submitted in separate specimen pots appropriately labelled. The label should clearly state if:

- each polyp has been endoscopically removed (intact or piecemeal) or only biopsied or partially removed
- a polyp has been biopsied multiple times or removed piecemeal (to avoid misinterpretation as multiple polyps)

4. Specimen handling

BCSP specimens are no different to those originating from non-BCSP endoscopic or surgical practice and should be handled according to the routine laboratory procedure for such specimens. Most are received in the laboratory in formalin, and local excision specimens may be pinned to cork and orientated with sutures. After adequate fixation, for at least 4 hours but typically overnight, endoscopic biopsy specimens are transferred to cassettes for processing, with the number of mucosal fragments in each specimen recorded.

4.1 Measurement

Polypectomy specimens should be macroscopically measured in 3 dimensions in millimetres (mm). Rounding up or down (terminal digit preference) should be avoided. It is recommended that these measurements are recorded in a systematic fashion, for example length x breadth x height, with an indication of any stalk present (with its measurement). This conveys the maximum macroscopic information to the reporting pathologist.

Given the clinical significance of adenoma size, notably around the 10mm diameter cut-off, it is important that larger polyps received intact are sectioned along their longer axis if possible, so that the maximum dimension can be presented on the glass slide for microscopic measurement (7). If the largest axis within an intact polypectomy specimen is not presented on the glass slide, it is important that this information is conveyed to the reporting pathologist by the dissector to avoid potential underestimation of overall adenoma size.

4.2 Sectioning

Sectioning should be perpendicular to the polyp base excision margin if this is identifiable. Inking of the polyp base is not considered necessary on a routine basis as

the excision margin is usually readily identifiable microscopically, often through the presence of diathermy artefact.

Polyps with a narrow stalk should be trimmed to keep the stalk intact and orientated to allow clear microscopic visualisation of the polyp base margin, through multiple levels if necessary. Polyps with a broader stalk ('semi-pedunculated') or sessile polyps should be serially sectioned at 3mm intervals, perpendicular to the base margin if this is identifiable. All tissue should be processed for histological evaluation.

Careful liaison between dissector and reporting pathologist is vital so that the dimensions of the specimen and the mode of dissection are understood. This approach enables accurate assessment at microscopy of the maximum dimension of any adenomatous component of the polyp (section 5.2.2). This measurement of adenoma sizes will be used to inform individual risk stratification and recommend the surveillance interval for any follow-up colonoscopy (7).

4.3 Margins

If there is any suspicion of malignancy within a local excision specimen at endoscopic procurement or at dissection, it is advisable to paint any identifiable resection margins (mucosal and/or deep) to ensure subsequent microscopic identification. If any mucosal lesion has a surrounding mucosal margin of normal tissue that macroscopically measures less than 3mm, this margin should be examined perpendicularly by taking sections of the margin at right angles from a thicker slice. Macroscopic images are helpful to illustrate margin status and block sampling.

5. Reporting non-invasive lesions

5.1 Data

Unpublished histopathology data derived from 558,637 non-invasive lesions diagnosed at screening colonoscopy since inception of the English programme revealed that:

- just over 70% were classical adenomas (55% tubular adenoma, 15% tubulovillous adenoma, <1% villous adenoma)
- 19% were hyperplastic polyps
- <1% were reported as sessile serrated lesions, although this percentage is likely to grow as this entity was likely under-recognised in the early years of the programme
- all other diagnoses comprise <3% of all lesions (Table 1)

Other diagnoses included traditional serrated adenoma, inflammatory and post-inflammatory polyps, a wide range of benign mesenchymal polyps, and juvenile type, Peutz-Jeghers type and other hamartomatous polyps. Individually, these specific diagnoses are all rare in BCSP practice.

Table 1. Frequencies of common histopathological diagnoses from non-invasive lesions detected during screening colonoscopy since inception of the English Bowel Cancer Screening Programme to April 2006 - May 2017

Lesion	Percentage
Tubular adenoma	54.7%
Tubulovillous adenoma	15.2%
Villous adenoma	0.8%
Hyperplastic polyp	19.2%
Mixed hyperplastic polyp/adenoma	0.3%
Serrated adenoma	0.7%
Sessile serrated lesion	0.5%
Traditional serrated adenoma	0.1%
Inflammatory polyp	1.2%
Not polyp	5.7%
Lipoma	0.1%
Lymphoid polyp	0.1%
Other polyp	0.5%
Not recorded	0.9%
Total	100%

5.2 Classical adenomas

5.2.1 General comments

The World Health Organisation (WHO) classification of premalignant epithelial lesions or adenomatous polyps is recommended (8). By definition, adenomas must show dysplasia (intraepithelial neoplasia). Classical adenomas are divided into tubular, tubulovillous and villous types. Demarcation between them is based on the relative proportions of tubular and villous components.

The term 'advanced adenoma' (mainly employed in United States screening literature) most commonly describes any adenoma that is $\geq 10\text{mm}$, has a villous component $>25\%$

(villous or tubulovillous) or has high grade dysplasia (9). This term should not be used without a clear indication of its meaning, so as to avoid confusion with terms used in risk stratification based on number and size of adenomas only (7).

5.2.2 Sizing

As discussed in section 4, accurate polyp sizing requires careful macroscopic and microscopic correlation. The current available evidence indicates that the pathology size of adenomas is more accurate and reliable than the endoscopy size. It is mandated that the pathology size of adenomas is used for clinical decision making if both sizes are available (10,11,12).

For adenomas, the aim of the reporting pathologist should be to provide the single maximum dimension of the adenomatous component of the polyp. In many cases, this will equate to the maximum macroscopic dimension of the formalin-fixed polyp, if all or almost all of the polyp is adenomatous.

In some adenomas, large size or unusual configuration may preclude representation on the glass slide of the largest polyp axis. In such cases, if microscopy demonstrates that the entire polyp is adenomatous then the largest macroscopic dimension of the polyp, after formalin fixation, can be safely recorded as the maximum adenoma diameter. If the polyp includes a non-adenomatous component, then the maximum microscopic dimension is recorded (Figure 1).

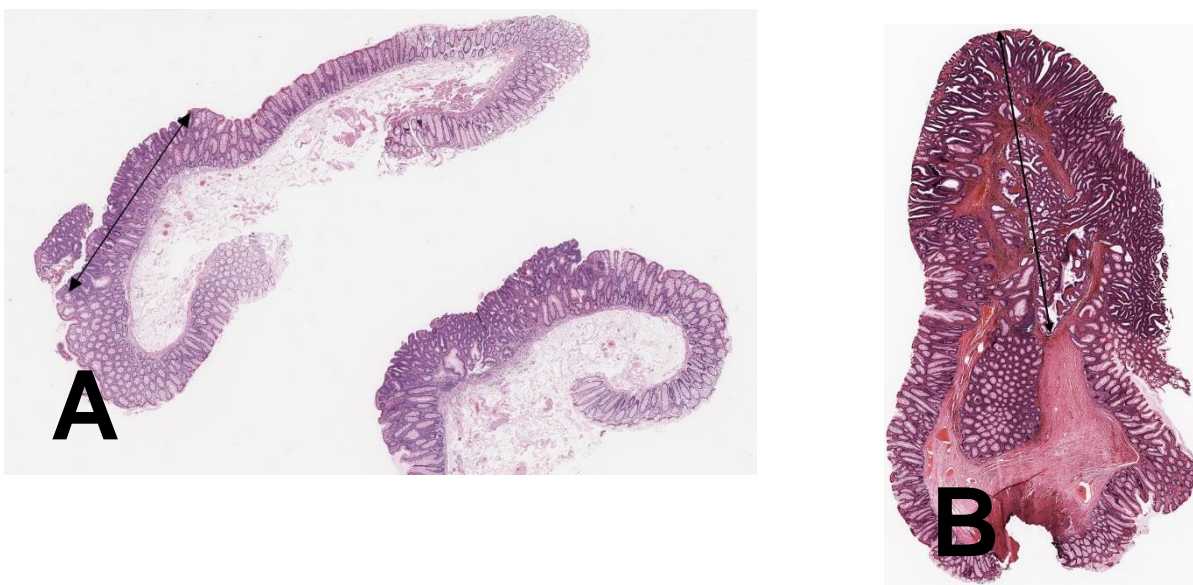


Figure 1: measuring adenomas

A. Bisected polypectomy specimen in which only part of the specimen is adenomatous. In such cases, the maximum microscopic dimension of the adenomatous component should be recorded as the adenoma size. In this case, the adenoma size (arrow) is 4mm, compared to 11mm maximum macroscopic dimension of the fixed polypectomy specimen.

B. Occasionally, the maximum microscopic dimension of an adenoma may be a vertical measurement. Correlation with macroscopic assessment of overall polyp dimensions is important and care should be taken not to include any non-adenomatous polyp stalk or non-adenomatous epithelial misplacement in the adenoma measurement. In this case, the adenoma size (arrow) is 6mm, compared to 10mm maximum (vertical) dimension of the entire polypectomy specimen.

Measurement should be via the BCSP graticule or an ISO accredited graticule if measuring on the glass slide. Size should be measured to the nearest millimetre and not rounded up or down to the nearest 5 or 10mm (terminal digit preference bias).

If a polyp is received piecemeal, or if a non-excision biopsy only is received, then pathology size is not assessable and should be recorded as such. Recording sizes of individual piecemeal fragments received is potentially confusing and not recommended. In these circumstances, the endoscopic size should be used to determine follow-up.

Endoscopic sizing may take place in vivo assisted by size comparison to open biopsy forceps, or after excision from within the specimen container. As audit of endoscopy versus pathology size is an endoscopic quality measurement, care should be taken not to record the endoscopy size under the pathology size.

5.2.3 Villousness

Villousness (a tubulovillous or villous morphology) has long been used as one of the 3 criteria for designating an adenoma as 'advanced' in nature; in other words, associated with an increased risk of synchronous or subsequent CRC. The other 2 'defining' features in this regard are:

- adenoma size 10mm or greater
- the presence of high grade dysplasia (13)

Associations have been demonstrated between all 3 of these features. Larger adenomas also tend to show greater villousness and a higher incidence of high grade dysplasia. Increasing villousness below the threshold required for a diagnosis of tubulovillous adenoma has been associated with the acquisition of molecular alterations (for example KRAS mutations) that are characteristic of tubulovillous adenomas (14). It is less clear whether villousness alone is an independent risk factor for the presence of synchronous or metachronous CRC (regardless of the size of the adenoma and the presence or absence of high grade dysplasia).

Data derived from BCSP in England (2006 to 2017) indicates that around 8% of all adenomas reported in BCSP are tubulovillous adenomas measuring up to 10mm in diameter and showing low grade dysplasia. These lesions would be assessed as 'advanced' in nature based solely on their villousness (section 5.2.1). This data also

indicates that in adenomas up to 10mm in size, high grade dysplasia is identified in 0.6% of those assigned as tubular but in 3.7% of those assessed as tubulovillous.

Accurate and reproducible identification of 'advanced' adenomas (those with size ≥ 10 mm, a villous component $>25\%$ or high grade dysplasia) has become relevant in the UK with the introduction of flexible sigmoidoscopy-based screening (bowel scope) within the NHS BCSP, since the finding of such an adenoma in this setting will trigger consideration for full colonoscopy within this programme (15). Inter-observer agreement during the assessment of polyp features, particularly villousness, is poor (16,17,18).

It is recommended not to use the term 'advanced adenoma' in pathology reporting but instead to detail each of the relevant pathology features (see section 5.2.1).

One potential solution to the difficulty of reproducibility might be to remove villousness from the list of features that define an adenoma. Since increasing adenoma size is closely linked with the presence of high grade dysplasia, size may be the most practical determinant, within an individual lesion, of subsequent CRC risk (19). However, there is not currently enough data relating to the risk for synchronous or metachronous CRC that may be conferred by villousness when this feature is the only criterion of 'advanced' adenoma that is present. Until more data is available regarding its potential independent biological significance, villousness should remain one of the criteria assessed in reporting adenomas, but improved reproducibility of its assessment is needed.

It is difficult to arrive at a definition of villousness that would facilitate recognition of this feature with a high degree of inter-observer agreement. However, the following descriptors and minimum criteria are recommended.

Descriptors of villousness

- Classical villi are finger-like up growths of neoplastic epithelium with a stromal core comprising lamina propria.
- The sides of classical villi are often parallel but the tips may be bulbous.
- Palmate villi have a more complex, branched and/or leaf-like architecture.
- Tangential cutting may result in palmate villi having the appearance of tubular glands.
- Villi may extend down to the muscularis mucosae or, in the case of an adenoma with a mixed tubular and villous architecture, protrude from the otherwise smooth contour that is imparted by the tubular component of the lesion.
- The invaginations that are sometimes seen within adenomas that have an otherwise tubular morphology do not constitute villi if the overall surface contour of the lesion is smooth.

Minimum criteria for categorisation

1. At least 25% of an adenoma is required to possess a villous architecture in order for the lesion to be categorised as a tubulovillous adenoma (8). Adenomas in which a villous component comprises less than 25% of the lesion are designated as tubular adenomas. Adenomas in which a villous component comprises more than 75% of the lesion are designated as villous adenomas. As villous adenomas are rare, tubulovillous and villous adenomas are usually grouped together (any adenoma with a significant (>25%) adenomatous component).
2. Within biopsies of larger lesions, any degree of villousness should raise the possibility that the lesion is tubulovillous or villous in nature and result in the categorisation of a lesion as a tubulovillous (or villous) adenoma.

As a guide, no more than 25% of colorectal adenomas should be designated as tubulovillous in nature. Unpublished data derived from BCSP in England (2006 to 2017) indicates that 75% of more than 265,000 colorectal adenomas reported were classified as tubular in nature. Pure villous adenomas are rare in the screening programme.

Images designed to illustrate the above descriptors are shown in Figure 2. These images are included to support improvement in consistency of reporting of villousness in colorectal adenomas and facilitate the future determination of the relative importance of this feature in the designation of adenomas as 'advanced'.

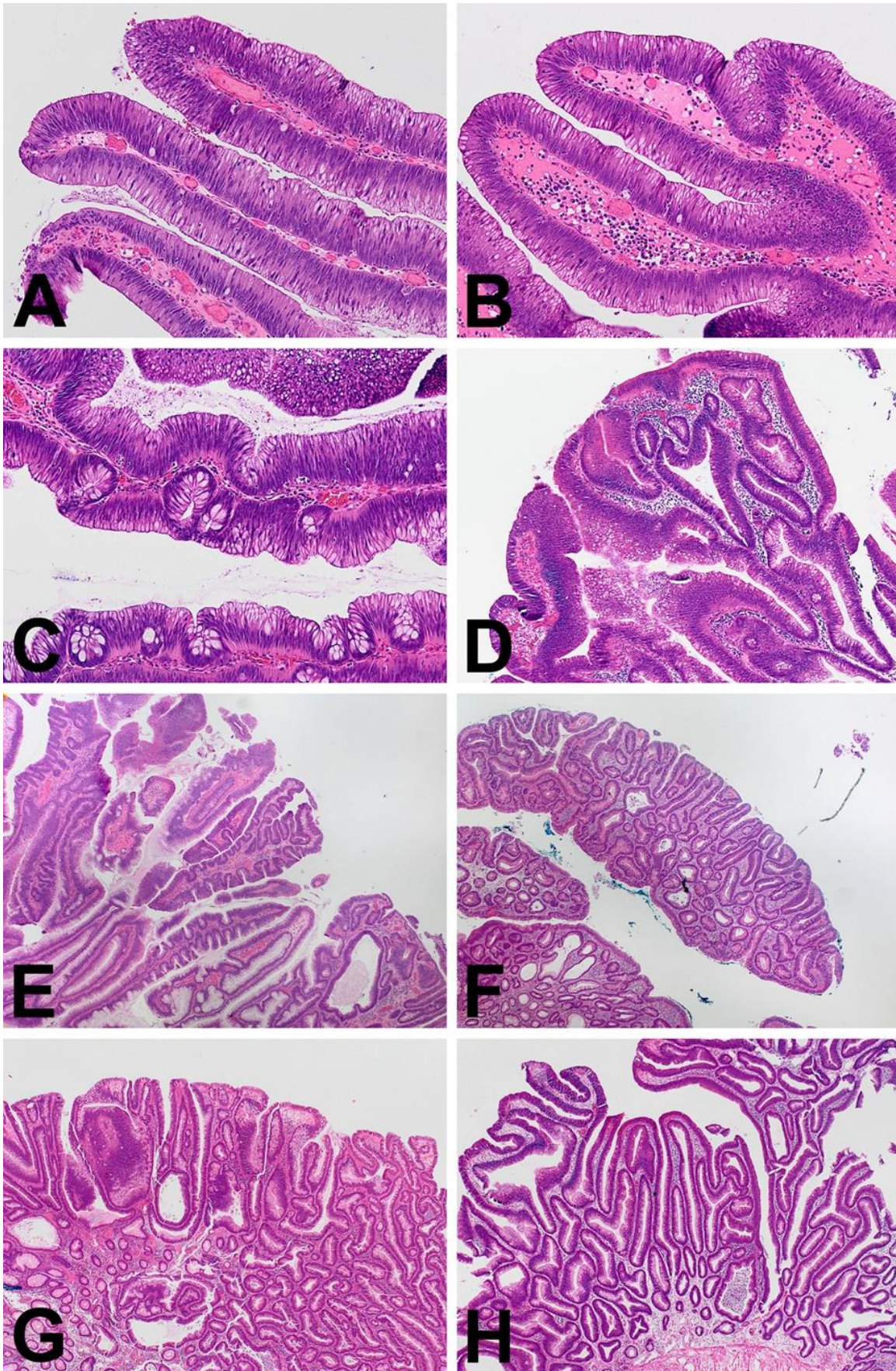


Figure 2: Features of villousness

(Figure 2 cont.)

- A.** Typical slender villi, with parallel edges and a core of lamina propria.
- B.** Villi with a slightly more complex, branched growth pattern.
- C.** Villi containing ectopic crypts, leading to a more complex appearance that should not be mistaken for high-grade dysplasia. Although considered an important feature of traditional serrated adenoma, ectopic crypt foci are also commonly seen in tubulovillous adenomas
- D.** Tangential cutting leading to accentuation of the complex nature of this villiform area, with the juxtaposition of villous and tubular structures.
- E.** A villiform growth pattern is present centrally and on the left side of this image. Despite the relatively smooth overall contour of the polyp within this area, there is sufficient evidence of villousness for this to be assessed as villous in nature.
- F.** An adenoma that is fragmented, with some clefting. However, villousness is not present and this should be assessed as a tubular adenoma, noting the overall smooth surface contour.
- G.** Clefting is present on the left side of this image, leading to borderline villousness within a polyp that still shows a smooth overall contour. These features are insufficient to be assessed as villous.
- H.** An area of established villousness, showing several villous structures that appear to 'originate' approximately halfway between the muscularis mucosae and the polyp surface, but with one such structure on the right side of this image appearing to extend almost from the level of the muscularis mucosae.

5.2.4 Grading dysplasia

A 2-tier stratification of adenomatous dysplasias is now widely accepted. The terms used are:

- low grade
- high grade

This affords greater reproducibility and provides a uniform system for integrating global (particularly Western and Japanese) histopathology grading data (8). The terms mild, moderate or severe dysplasia should not be used.

The changes of high grade dysplasia should usually involve more than just one or two glands (except in tiny biopsies of polyps), enough to be identified at low power examination. Caution should be exercised in overinterpreting isolated surface changes that may be due to trauma, erosion or prolapse. Similarly, crush artefact should not be interpreted as glandular complexity. High grade dysplasia is primarily diagnosed on architecture, supplemented by cytology. This means its presence is nearly always suspected by the appearance under low power of complex architectural abnormalities in structures whose epithelium looks thick, blue, disorganised and 'dirty'. The architectural features of high grade dysplasia are:

- complex glandular crowding and irregularity
- a cribriform appearance and 'back to back' glands

- prominent intraluminal papillary tufting

Although many of these features often coexist in high grade dysplasia, individually they are neither necessary nor usually sufficient. Indeed, they may occasionally occur in lower grades of dysplasia, which is why it is also necessary to scrutinise the cytological features for signs of high grade dysplasia. The cytological features are:

- loss of cell polarity or nuclear stratification to the extent that the nuclei are approximately equally, though haphazardly, distributed within all 3 thirds of the height of the epithelium
- markedly enlarged nuclei, often with a dispersed chromatin pattern and a prominent nucleolus
- atypical mitotic figures
- prominent apoptosis, giving the epithelium of the lesion a 'dirty' appearance

Again, these features usually coexist in high grade dysplasia, and caution must be exercised in using just one feature to make the diagnosis. It should be emphasised that these cytological features should occur in a background of complex architectural abnormality to allow classification as high grade dysplasia. Marked loss of polarity and nuclear stratification sometimes occur on the surface of small, architecturally regular, tubular adenomas that otherwise have features of low grade dysplasia (probably as a result of trauma or ulceration) and must not be used to classify a lesion as high grade. The only potential exception to the rule is when the specimen consists of a small biopsy from the surface of a polyp – when there is insufficient tissue to assess the architecture properly. In this situation, it is permissible to regard marked cytological abnormalities alone as high grade dysplasia, but this will usually lead to excision of the whole polyp so it will become possible to assess the whole lesion properly.

Examples of low and high grade dysplasia are illustrated in Figure 3.

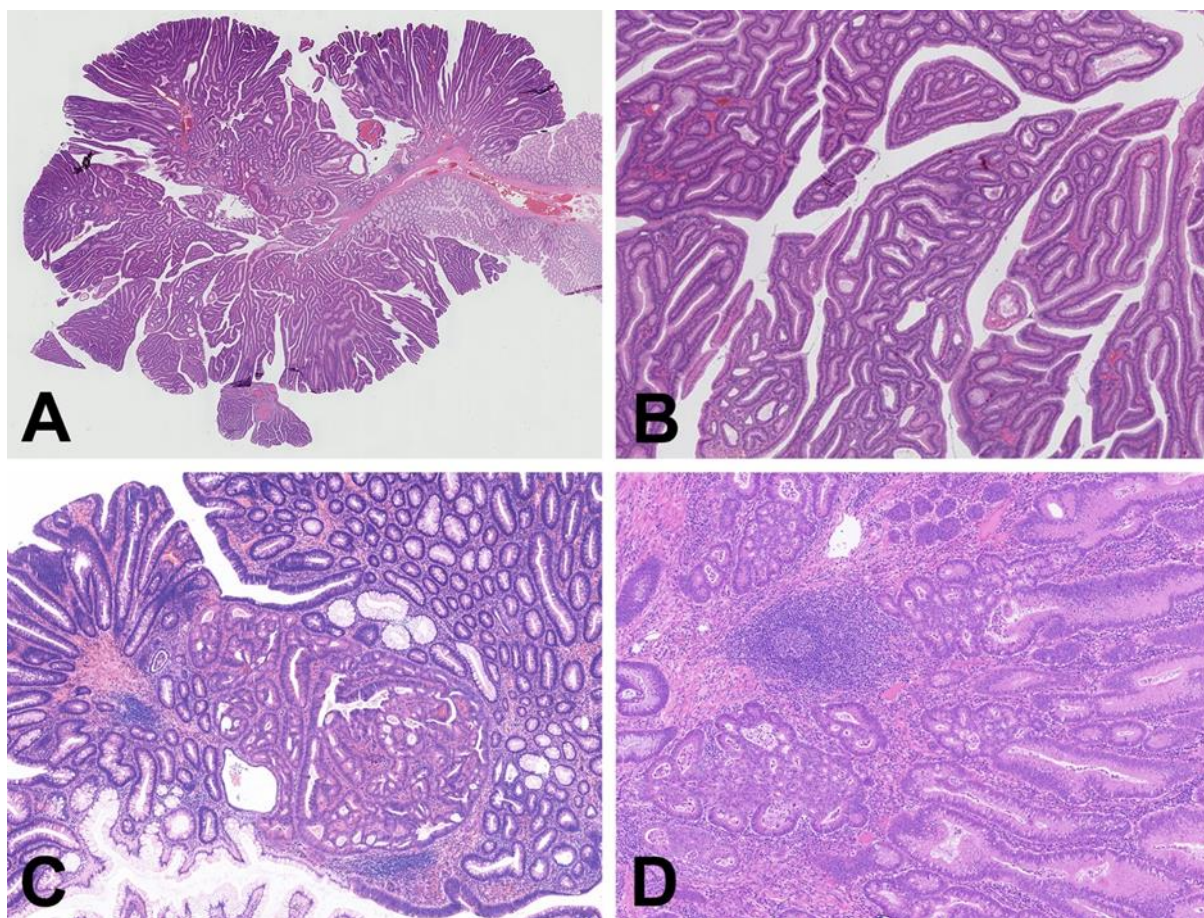


Figure 3: Low and high grade dysplasia

A. An adenoma with predominantly villous architecture; even on low power magnification, the lack of any complex architectural features suggests low grade dysplasia throughout.

B. higher magnification of the same adenoma confirms architectural and cytological features of low grade dysplasia.

C and D. Two separate adenomas, each demonstrating focal high grade dysplasia, with complex glandular crowding and irregularity, a cribriform appearance and luminal necrosis. Higher magnification to confirm the corresponding cytological features is rarely necessary given these low power appearances.

5.2.5 Assessment of polypectomy margin

The endoscopist should remove all adenomatous polyps completely so as to prevent progression to adenocarcinoma. Ideally, removal should be in one piece to optimise histopathological assessment of the lesion. Larger polyps may require removal in multiple steps, resulting in a piecemeal polypectomy specimen.

Regardless of the nature of the specimen, the endoscopic impression of completeness of excision should be conveyed on the pathology request form. The endoscopist's impression is typically more valuable than that of the pathologist, who can comment only on any involvement of a diathermied margin by dysplasia (and specify high or low grade) within an intact polypectomy specimen. This does not equate to incomplete

excision as diathermy may destroy a zone (up to several millimetres) of normal tissue, creating the impression of incomplete excision. Therefore, the phrase 'involvement of diathermied margin by dysplasia' is preferred when diathermy artefact is seen.

It should be emphasised that the vast majority of small polypectomy specimens are not oriented and residual margin involvement by dysplasia is not assessable. Similarly, no useful comment can typically be made on margin involvement by dysplasia within a piecemeal polypectomy specimen unless a fragment specified as the margin has been clearly indicated.

It is not considered necessary to comment on the polypectomy margin for hyperplastic polyps.

5.2.6 Epithelial misplacement

Epithelial misplacement of adenomatous epithelium into the submucosa of a polyp is a well-recognised phenomenon, particularly common in large prolapsing polyps in the sigmoid colon. Distinction of epithelial misplacement, or so-called 'pseudoinvasion', from invasive adenocarcinoma is perhaps the single most difficult area of pathological diagnostic practice in BCSP pathology assessment. Large sigmoid colonic polyps are particularly prone to inflammation and ulceration, features which tend to enhance the dysplastic changes. When associated with epithelial misplacement, the potential for misdiagnosis of early adenocarcinoma (stage pT1) increases and the overall diagnostic difficulties become greater.

Double reporting by BCSP pathologists of all cases of endoscopically resected stage pT1 CRC is now mandatory in BCSP pathology practice. This is because misdiagnosis of adenocarcinoma may lead to an inappropriate major surgical intervention. Despite increased awareness of the problem and enhanced recognition of the classical features of epithelial misplacement versus adenocarcinoma (Table 2), many cases are highly problematic as the features presented are overlapping. Figure 4 illustrates some examples.

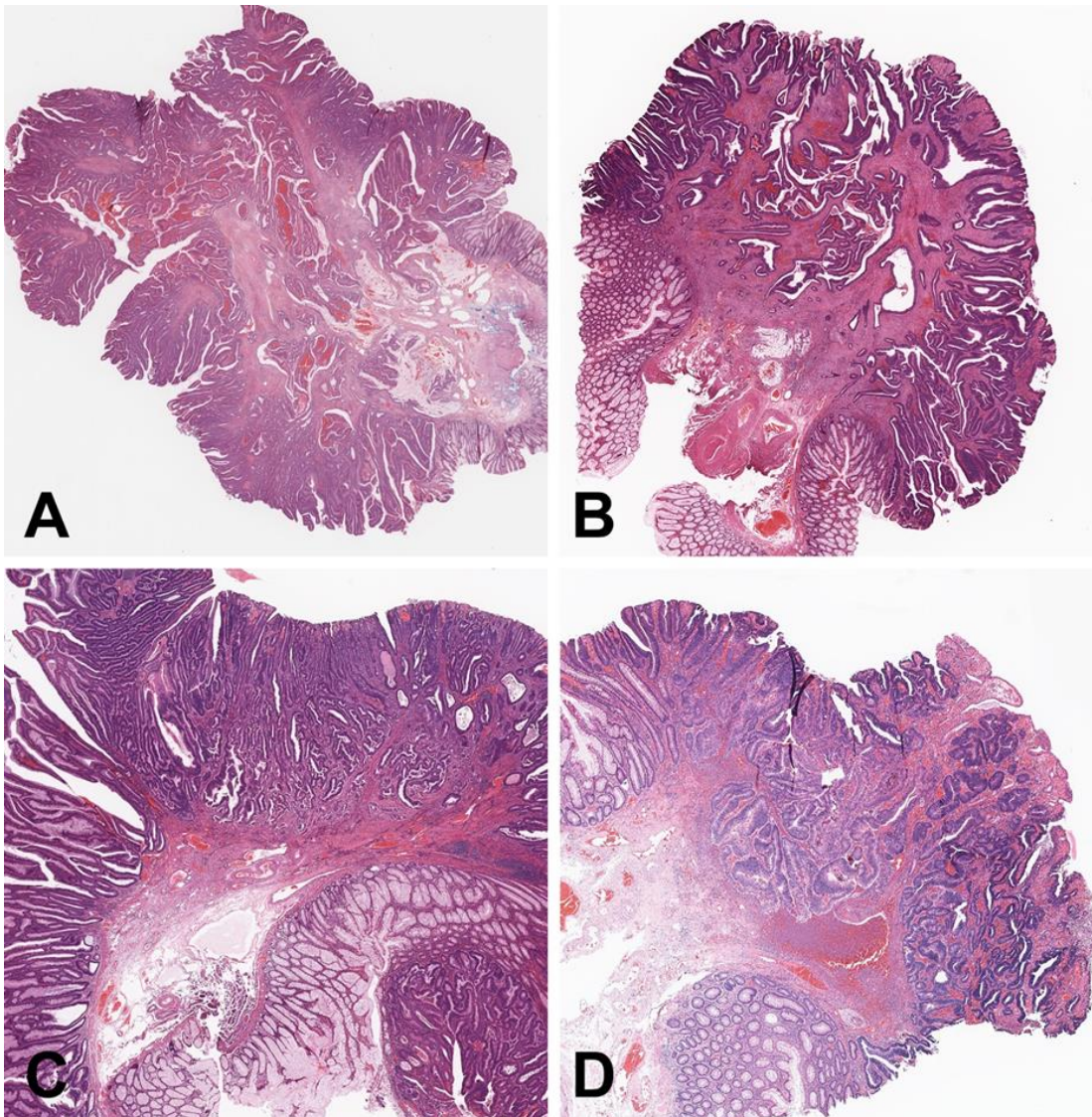


Figure 4: Epithelial misplacement versus early adenocarcinoma

Low power views of four polyps are presented to illustrate the important features evident at this magnification.

A. Classical features of epithelial misplacement with a lobulated glandular arrangement, surrounding lamina propria rather than desmoplastic stroma, dysplastic change in continuity with surface adenoma and vascular congestion, haemorrhage and mucin extravasation resulting from gland rupture.

B. Well differentiated adenocarcinoma featuring haphazardly infiltrating glands eliciting a desmoplastic stromal reaction.

C. A focal area of submucosal invasion within a tubulovillous adenoma. Note the thin band of intact muscularis mucosae towards the lateral aspects but central destruction of muscularis mucosae associated with small infiltrating glands.

D. A difficult case featuring glands with high grade dysplasia located within the submucosa of the polyp head. A lobular architecture is retained and there is probable gland rupture with adjacent abscess formation favouring benignity, but confident distinction from an early adenocarcinoma is not possible.

Polyps demonstrating the classical misplacement features of lobulated glands, surrounding lamina propria, haemosiderin deposition and prolapse-type muscular stroma usually provide no diagnostic problems. However, many cases show only some of these appearances, often accompanied by more concerning morphological features, such as apparent desmoplastic stroma, haphazard glandular 'pseudoinfiltrative' pattern, glandular angulation or single cells lying within stroma. The most difficult cases often include misplaced glands showing high grade dysplasia, associated with gland rupture, mucin extravasation and secondary inflammatory changes. The correct diagnosis in such cases may be almost impossible to determine. Previous biopsy or partial polypectomy may also induce mucosal necrosis, ulceration with regenerative atypia and/or a desmoplastic stromal reaction, strongly mimicking malignancy. Any previous intervention should always be conveyed on the pathology specimen request form.

BCSP pathologists can access an 'expert board' whereby these difficult diagnostic problems of epithelial misplacement versus polyp cancer are assessed by 3 specialist gastrointestinal pathologists. The current coordinator is Professor Neil A Shepherd at Cheltenham (address given at the front of this document) and all such cases should be sent initially to him. PHE currently fund the board and consequently there is no charge for this specialist diagnostic service. The results for the first 5 years of these assessments have been published (20).

Overall judgment must be based foremost on appropriate clinical management. If surgical intervention would not be warranted in a given case, regardless of a diagnosis of epithelial misplacement or adenocarcinoma (stage pT1 with no adverse features and clear margins), it is considered prudent to reserve a diagnosis of malignancy for those cases with considerable certainty in the diagnosis.

Table 2. A comparison of the pathological features for differentiating epithelial misplacement from invasive adenocarcinoma (reproduced with permission from (21))

	Epithelial misplacement (EM)	Adenocarcinoma
Epithelial 'differentiation'	Usually similar to that of the surface adenomatous component	Variable and usually different to the surface adenomatous component
Lamina propria accompaniment	Characteristic but may be lacking when there is secondary inflammation and epithelial destruction	Usually absent. Can be present in rare, very well-differentiated carcinoma
Accompaniment by non-adenomatous epithelium	Characteristically seen when EM is due to previous intervention	Absent
Haemosiderin deposition	Characteristic and indicative of previous necrosis and/or haemorrhage	Usually absent
Mucosal prolapse changes	Often present	Usually absent
Mucus cysts	Characteristic. They probably represent epithelial misplacement that has become 'detached' from the more superficial components	Only present, usually, in mucinous tumours
Continuity with surface adenomatous component	Characteristic but often only appreciated in multiple levels and/or 3D reconstruction studies	Usually absent but some cases do show continuity, even in 3D reconstruction studies.
Involvement of muscularis propria (MP)	Usually absent. Can be seen very rarely, especially after previous intervention	Present if at least pT2
Budding	Usually absent but a similar phenomenon can be seen as a result of epithelial destruction and/or inflammation	Often present
Desmoplastic reaction to glands	Usually absent but fibromuscular stromal proliferation can accompany EM	Usually present
Lymphatic and/or vascular invasion	Absent	Diagnostic of cancer

5.3 Serrated lesions

The histopathological assessment of serrated colorectal lesions can be a problematic area. The terminology used to describe lesions within this spectrum is variable and the suggested minimum diagnostic criteria for some lesions differ between authorities. One of the most difficult areas is the nomenclature of, and diagnostic criteria for, sessile serrated lesions (SSL) (also termed sessile serrated polyp, sessile serrated adenoma or sessile serrated adenoma/polyp). This is particularly important as these lesions, while bearing histological resemblance to hyperplastic polyps (HP), may be associated with the earlier development of epithelial dysplasia and adenocarcinoma. This topic is the subject of a recent review, an edited version of which forms the basis of the advice given within this document (22).

Lesions with serrated morphology should be given one of the following names according to their morphological features:

- hyperplastic polyp (HP)
- sessile serrated lesion (SSL)
- sessile serrated lesion with dysplasia
- traditional serrated adenoma (TSA)
- mixed polyp

5.3.1 Hyperplastic polyps (HPs)

HPs are small serrated lesions showing no features that would allow categorisation as SSL and no evidence of dysplasia. We use the term 'dysplasia' in this context to refer to the morphological appearances of epithelial neoplasia within the mucosa of the colon and rectum – for example, the epithelial changes recognised by histopathologists as characteristic of 'classical' adenomas.

HPs are usually small (less than 5mm diameter) and may occur anywhere within the colon and the rectum. However they are particularly common in the distal colon and rectum and are often multiple. There are 2 common morphological forms of HPs.

1. Microvesicular HP. These demonstrate vesicular mucin-containing epithelial cells and goblet cells are decreased in number compared with normal crypts. Goblet cell-rich HPs account for about a third of all hyperplastic polyps and these, too, almost always occur in the left colon and rectum. Unsurprisingly, they show numerous goblet cells. Microvesicular HPs tend to demonstrate BRAF mutations whereas KRAS mutations are predominant in the goblet cell-rich variant.
2. Mucin-poor HP variant. This type is rare and is similar to the microvesicular HP but contains less microvesicular mucin and less goblet cells.

The cancer risk associated with small HPs is very low.

5.3.2 Sessile serrated lesions (SSLs)

SSLs are synonymous with the sessile serrated adenoma/polyp in the current WHO classification and the latter terminology is in common use, particularly in North America (23). When 'pure', these lesions show no evidence of dysplasia but, in comparison to HPs, they contain one or more of the following histopathological features:

- irregular distribution of crypts
- dilatation of crypt bases
- serration present at crypt bases
- branched crypts
- horizontal extension of crypt bases
- herniation of crypts through the muscularis mucosae (Figure 5)

SSLs also show 'dysmaturation'. This is a disorganised arrangement of proliferating cells and goblet cells within the lower half of the crypts, with subtle cytological abnormalities that are more pronounced than in hyperplastic polyps. Some pathologists believe that 'dysmaturation' represents a form of dysplasia but these changes are distinct from those that are recognised as dysplasia within 'classical' adenomas.

Opinion in the UK is that the term 'adenoma' is inappropriate for a lesion in which morphological dysplasia is not demonstrable and hence we would not use the term sessile serrated adenoma for such a lesion. Use of the WHO diagnostic criteria (for sessile serrated adenoma/polyp) is recommended – the presence of 3 (or 2 adjacent) characteristic crypts, as a minimum diagnostic requirement (24).

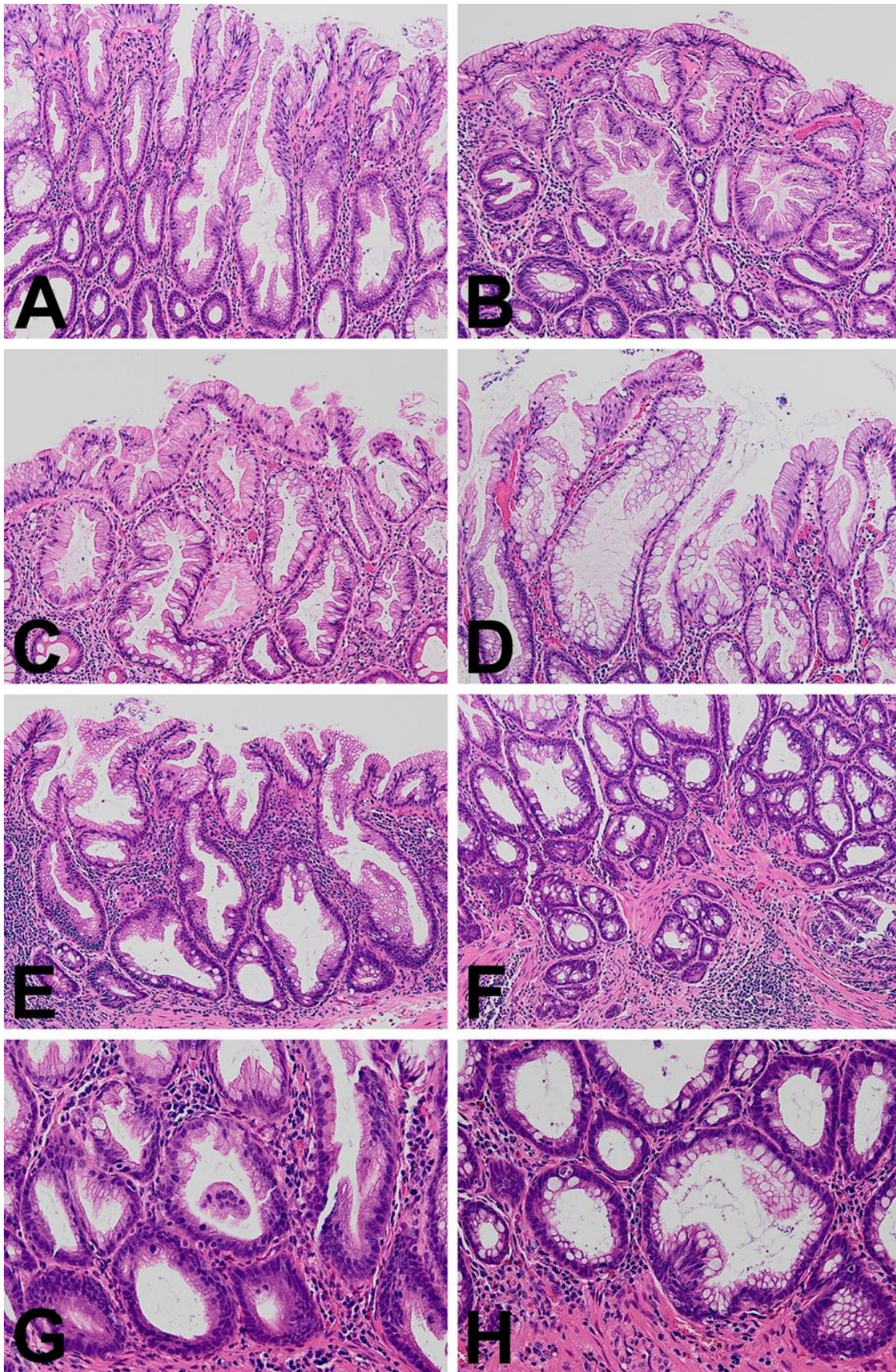


Figure 5: Histology of sessile serrated lesions

Figure 5 (cont.)

- A. Branched crypts.
- B. Pronounced serration.
- C. Horizontal extension of crypt bases.
- D. Surface villousness.
- E. Crypt dilatation.
- F. Herniation of crypts through muscularis mucosae.
- G and H. Crypt bases showing 'dysmaturation', evidenced by nuclear enlargement, hyperchromasia, stratification and apposition of goblet and non-goblet cells.

HPs and SSLs share many morphological features and both are associated with mutations in the BRAF gene (25). It is therefore possible that they represent part of the same 'spectrum' of serrated lesions, with small HPs at one end and larger (10mm+) SSLs at the other. The condition originally termed 'hyperplastic polyposis' is now termed 'serrated polyposis' after the morphological features of SSLs were identified in this setting. In this model, it is unclear why tiny, often distal, HPs do not appear to be associated with a significant risk of CRC development, while larger lesions with the features of SSLs can be associated with the development of dysplasia and adenocarcinoma.

5.3.3 Sessile serrated lesions with dysplasia

SSLs may contain a focus of dysplasia as defined above. This dysplasia may be low or high grade in degree and is almost invariably present within a lesion that shows background features of a sessile serrated lesion without dysplasia. It has been suggested that these lesions may be associated with faster progression to adenocarcinoma than 'classical' adenomas. The term 'mixed polyp' has previously been used to describe this lesion (see below). Dysplasia arising in the context of an SSL commonly shows loss of immunohistochemical expression of the DNA mismatch repair enzyme hMLH-1, as part of a genetic signature that includes BRAF mutation and widespread DNA methylation (the 'CpG island methylator phenotype' - CIMP) (26). Most so-called mixed polyps, especially in the right colon, are likely to represent various stages in the serrated neoplasia pathway, namely the presence of an SSL within which dysplasia has arisen.

5.3.4 Traditional serrated adenomas (TSAs)

TSAs are distinct from SSLs. They most commonly occur in the distal colon and rectum and may have a pronounced villiform or even filiform architecture. They are characterised by the presence of dysplasia (often subtle) together with a variable proportion of the lesion showing eosinophilic cytoplasm, pencillate nuclei and ectopic crypts. The serration in TSAs is imparted by a combination of undulations in the crypt epithelium and crypt budding. TSAs almost always comprise a mixture of foci showing

the above characteristic features with areas showing a 'classical' adenoma growth pattern, in which obvious dysplasia is present. The proportion of areas showing the characteristic TSA features and 'classical' adenoma features is variable and the minimum criteria for a diagnosis of TSA are not well defined. Molecular analysis has revealed that TSAs more commonly possess KRAS mutations and less commonly harbour BRAF mutations than SSLs (25). For these reasons, TSAs appear to be more closely related to 'classical' adenomas than SSLs.

TSAs are characterised by a disruption of the signalling pathways involved in stem cell control and cell fate determination. This results in the expansion of a progenitor cell population from the crypt base into the ectopic crypt foci or lateral buds that morphologically characterise this condition. These progenitor cells actively proliferate and accumulate somatic mutations with resultant dysplasia arising from outside the crypt base stem cell niche (27). This may be why TSAs seem to have a more rapid malignant potential compared to 'classical' adenomas, as the ectopic crypt foci/lateral buds act like extra crypt cell niches and are subject to additional mutations.

5.3.5 Mixed polyps

It is likely that the majority of 'mixed' polyps, especially in the right colon, represent SSLs with and without dysplasia. However polyps may rarely be encountered, particularly in the left colon, that appear more likely to have arisen due to a true 'collision' event between a HP and a 'classical' adenoma. Furthermore, TSAs in which a significant component shows the features of a 'classical' adenoma are also seen. The minimum proportion of a TSA that is required to show features of a 'classical' adenoma in order for the polyp as a whole to be considered 'mixed' has yet to be defined. Occasionally polyps showing a combination of SSL and TSA-like features are encountered, with or without areas with a 'classical' adenoma appearance. Another variant of the mixed polyp is the combination of HP changes and serrated low grade dysplasia with features of a TSA. These lesions are more unusual and are seen typically in the sigmoid colon and rectum. While a collision lesion is possible, we believe that the latter form of mixed polyp most likely represents different stages in the traditional serrated neoplasia sequence with serrated dysplasia deriving from a pre-existing HP.

Due to the existence of lesions such as these, it is sensible to retain the term 'mixed polyp' within the recommended terminology list, even if they may represent different serrated entities and different serrated neoplasia pathways.

Use of the term 'mixed polyp' should always be accompanied by a detailed description of the mixed features present and relative contributions to overall polyp composition. Where a lesion is showing a mixed type the management should be based on the most clinically important component.

5.3.6 Serration in other situations

It is now recognised that serration may be seen as a complication of chronic inflammatory bowel disease. The significance of isolated epithelial serration in ulcerative colitis in particular is currently uncertain. Serration may also be seen in dysplasia arising in the context of chronic idiopathic inflammatory bowel disease.

It also appears that epithelial serration, in the colon and rectum, can occur in other settings. For instance, epithelial serration is associated with stromal lesions, particularly small stromal polyps. Previously, this has been documented in colonic neurofibromas, perineuriomas and so-called 'benign fibroblastic polyp of the colon'. Further, particularly in the right colon, one may also see mucosal serration overlying submucosal lipomas. Although this might represent the coincidence of a sessile serrated lesion and an underlying lipoma, there is recent unpublished literature to suggest that this may represent divergent differentiation in the same lesion. Evidence for the latter has certainly accrued for the combination of serrated pathology and perineuriomatous proliferations (28,29,30). If in doubt please consider carefully whether any serration found is a distinct lesion or secondary to an underlying pathology.

5.4 Inflammatory polyps

Inflammatory-type polyps are relatively common in BCSP practice and represent a heterogeneous group. Although they are most usually seen as a complication of chronic idiopathic inflammatory bowel disease (particularly chronic ulcerative colitis) they are also frequently encountered in association with diverticulosis and/or mucosal prolapse. Furthermore, sporadic single inflammatory-type polyps are well described in the colorectum. As the reporting pathologist may not know the clinical context of such polyps, specifically the full colonoscopic appearances, we recommend that all such polyps are classified as 'inflammatory polyps'.

The morphological features may vary depending on the clinical context, but there is considerable overlap. Features may be sufficiently characteristic to allow diagnosis of a specific entity such as an inflammatory myoglandular polyp or colonic mucosubmucosal elongated polyp (CMSEP), entities reported to be distinct from other more common inflammatory and mesenchymal polyps (31,32). For the purposes of data recording such entities should also be included under the umbrella term 'inflammatory polyp'.

6. Reporting invasive neoplasia

6.1 Definition of invasion

The WHO recommended definition of colorectal adenocarcinoma is the one in everyday use within the UK, namely: “invasion of neoplastic glandular epithelial cells through the muscularis mucosae into the submucosa of the bowel wall” (8). This definition does not allow comparison with Japanese series, in which a diagnosis of carcinoma can be made on purely cytological grounds or in cases with invasion into the lamina propria but not beneath the muscularis mucosae. However it is consistent with United States and European literature and is also recommended in European guidelines for CRC pathology reporting (3).

This definition does not allow for the diagnosis of intramucosal carcinoma or stage pT in situ (pTis). Such terms are discouraged, to avoid overtreatment of lesions considered to have minimal or no risk of metastatic spread. The term high grade dysplasia should be used for such cases.

6.2 Reporting of diagnostic biopsy specimens

The definitive identification of adenocarcinoma in endoscopic biopsy specimens is one of the most difficult tasks faced by diagnostic pathologists reporting BCSP specimens. The diagnostic requirement to demonstrate submucosal invasion is problematic as submucosal tissue may not be represented in endoscopic biopsy material. Biopsies from endoscopically suspicious colorectal tumours therefore often fail to demonstrate clear-cut submucosal invasion. The presence of a desmoplastic stromal response to neoplastic glands is considered acceptable for a diagnosis of adenocarcinoma in most clinical circumstances, with the notable caveat to exercise caution in the context of previous endoscopic biopsies or partial polypectomy from the same site. Also juxtaposition of neoplastic glands to submucosal structures such as larger blood vessels, nerves and other neural structures may be sufficiently convincing to signify adenocarcinoma.

In the clinical context of a suspicious colonic mass on endoscopy and/or imaging which is locally unresectable, a histological diagnosis of primary glandular neoplasia – high grade dysplasia suspicious of adenocarcinoma or adenocarcinoma – is usually sufficient to proceed to surgery. More caution should be exercised with rectal lesions, given the greater number of therapeutic options for local excision and the higher morbidity of rectal surgery. Further, as rectal cancer is often treated with preoperative radiotherapy or chemoradiotherapy, it may be prudent to try to obtain a diagnostic

sample should any form of molecular assay subsequently be requested. Such assays are best performed on treatment-naïve tissue specimens.

In summary, it is recommended to report the features that are evident microscopically, and to determine clinical management at a multidisciplinary team meeting discussion. A histological diagnosis of CRC requires, as a minimum, either definite histological evidence of submucosal invasion or a desmoplastic reaction to neoplastic glands in the setting of a clinically evident malignancy.

6.3 Stage pT1 adenocarcinoma

It is beyond the scope of this document to discuss in detail reporting of CRC surgical resection specimens. Guidance produced by the Royal College of Pathologists (UK) for reporting CRC (including local excision) specimens is recommended (2). However, within screen-detected CRCs, a high proportion (up to 20%) are of early stage (stage pT1 or 'polyp cancers') compared to symptomatic CRCs.

While the principles of reporting local excision specimens are the same as in reporting major surgical resections, a number of features require special attention in reporting local excisions of presumed early cancers. This is because they are used to evaluate the need for further surgical intervention. Areas of attention include:

- an assessment of margins to indicate completeness of excision
- measurement of parameters that are considered to predict the presence of lymph node metastatic disease, specifically:
 - tumour size
 - differentiation
 - extent of submucosal invasion
 - presence of lymphatic or venous invasion

The core data items recommended in the RCPATH dataset (2) for recording are:

- specimen type (polypectomy, endoscopic mucosal resection, endoscopic submucosal dissection, transanal endoscopic microsurgical excision, local surgical excision, major surgical excision stating the type of operation and specimen removed)
- site of tumour
- overall specimen (usually polyp) size
- histological tumour type
- histological differentiation
- extent of local invasion
- lymphatic invasion
- venous invasion

- perineural invasion
- presence of a precursor lesion (or rarely other polyp type)
- margin involvement by carcinoma (deep/peripheral)
- minimum deep margin clearance of the invasive carcinoma (in millimetres)
- pT stage
- pN stage
- MMR/MSI tumour status, with an indication if the patient needs to undergo further testing for possible Lynch syndrome

6.4 Histological tumour type

Tumours should be reported using the WHO classification of 2010 (8). The vast majority of malignant colorectal tumours are adenocarcinomas. Variants worthy of recognition are:

- mucinous adenocarcinoma (adenocarcinoma with >50% composed of extracellular mucin)
- signet ring cell adenocarcinoma (adenocarcinoma with >50% signet ring cells)
- medullary carcinoma
- serrated adenocarcinoma
- cribriform comedo-type adenocarcinoma
- micropapillary adenocarcinoma

Some of these histological variants are associated with characteristic biological and/or clinical features. Mucinous, signet ring and medullary carcinoma, when associated with mismatch repair (MMR) deficiency, have an excellent clinical prognosis. Cribriform and micropapillary variants of adenocarcinoma tend to behave aggressively and, in the setting of early stage CRC, have been reported in multiple series to have a significantly increased risk of regional lymph node metastatic disease (28 to 31). All other carcinoma types are rare in the colon and rectum.

6.5 Histological differentiation

Differentiation of CRCs is based primarily on architecture and specifically gland or tubule formation (8). Poorly differentiated tumours demonstrate either irregularly folded, ill-formed, small tubules or no tubule formation at all. Poor differentiation in early stage CRC is a significant risk factor for regional lymph node metastatic disease, and therefore a potential indicator for surgical intervention. However most publications when assessing pT1 cancers fail to indicate whether poor differentiation is based on the predominant area or the worst area of differentiation within the tumour (37, 38).

As it is likely that most have used the worst area, in line with other guidance it is currently recommended that, in pT1 cancers only, poor differentiation should be based

on the presence of any area of definite poor differentiation until the situation is clarified by further research (2, 3).

This approach helps minimise the risk of patient under-treatment. However, tumour 'budding' alone is not considered morphological evidence of poor differentiation (section 6.10). It is emphasised that for stage pT2 CRCs and above, the predominant area should be used for grading differentiation as recommended by the RCPATH guidance, based upon the work of Halvorsen and others (39).

Poor differentiation and mucinous or signet ring cell morphology are among the morphological features suggesting involvement of the microsatellite instability (MSI) or mismatch repair (MMR)-deficient pathway to carcinogenesis (40). Other features include a medullary or solid architecture and prominent tumour-infiltrating lymphocytes. These features raise the possibility of underlying Lynch syndrome or, more likely in the age range of BCSP, sporadic MSI/MMR-deficient pathway CRC (40). There is considerable evidence that MMR-deficient CRCs have a better prognosis than MMR-proficient tumours (41,42). It is unclear if MMR status influences the significance of poor differentiation on lymph node metastatic risk in stage pT1 CRC, but it is possible that poor differentiation is only an adverse feature in MMR-proficient tumours, and should not be used as a factor triggering surgical intervention in MMR-deficient tumours. Further studies are required in this regard.

NICE recommends (4) that MMR immunohistochemistry/MSI testing is undertaken in all new diagnoses of CRC. Where this is not yet implemented, consider its use in cases of stage pT1 CRC diagnosed in the BCSP setting which demonstrate poor differentiation or other features suggestive of MMR deficiency (section 6.5). If MMR deficiency/MSI-high status is identified further testing (BRAF and hMLH1 methylation status) performed outside of the BCSP will be required to evaluate possible Lynch syndrome.

6.6 Extent of local invasion

A variety of descriptive or quantitative methods have been proposed for stratifying stage pT1 CRCs, mainly with the purpose of determining the risk of regional lymph node metastatic disease when the cancer has been removed by local excision. In stage pT1 CRCs, the frequency of lymph node metastasis in sessile tumours that involve the superficial, middle and deep thirds of the submucosa (so-called Kikuchi levels sm1, sm2 and sm3 respectively) has been reported to be 2%, 8% and 23% respectively (43,44).

In polypoid lesions, Haggitt and others identified the level of invasion into the stalk of the polyp as being important in predicting outcome and found that 'level 4' invasion, in which tumour extended beyond the stalk of the polyp into the submucosa, but did not invade the muscularis propria, was an adverse factor (45). However, neither the

Kikuchi nor Haggitt systems are easy to use in practice. Haggitt level is particularly difficult in polypoid specimens lacking a clearly defined stalk ('sub-pedunculated') or if the specimen is poorly orientated. Kikuchi level cannot be evaluated accurately without representation of muscularis propria in the specimen, to allow division of the submucosa into thirds. Such representation is rare in local excision specimens, with the exception of some transanally derived specimens.

Despite these limitations which result in a limited clinical utility of Haggitt and Kikuchi levels in routine practice, they should still be recorded where possible in the absence of strong evidence to recommend alternative approaches.

Ueno and others have proposed that the depth of invasion of tumour beyond the muscularis mucosae and width of the invasive tumour provide more objective measures of potential for lymph node metastasis (46). Both of these quantitative measurements should also be recorded, in millimetres, in line with the recommendation of the RCPATH dataset (2). Depth (or thickness) of invasive tumour should be measured from the muscularis mucosae where it is intact and identifiable. If the muscularis mucosae is obscured or destroyed by tumour, tumour thickness should be measured from the surface of intact mucosa or ulcer (47).

It is hoped that further evidence will be forthcoming to indicate which of these methods of assessment of extent of local invasion will be most useful for clinical management decisions. This is subject to ongoing study within the BCSP.

6.7 Lymphatic, venous and perineural invasion

Submucosal lymphovascular invasion, defined as tumour infiltration of endothelium-lined spaces in the submucosa, is regarded as a significant risk factor in local excision specimens for lymph node or distant metastatic disease. Two recent meta-analyses examining studies of stage pT1 CRC concluded that lymphatic invasion and, to a much lesser extent, venous invasion, are powerful predictors of lymph node metastatic disease (37, 38). Therefore it is now considered appropriate to attempt to evaluate lymphatic and venous invasion separately if possible.

It is important to distinguish lymphatic invasion from retraction artefact, and this may be assisted by application of D2-40 immunohistochemistry. This specifically identifies lymphatic channel endothelium and not venous channel endothelium (48, 49). Venous invasion is defined as tumour lying within an endothelium-lined space that is either surrounded by a rim of muscle or contains red blood cells (50). Elastic stains may highlight the rounded structure of a vein wall if tumour has obliterated the vein lumen (51). The greatest depth of lymphatic and venous invasion (intramural (comprising submucosal and intramuscular) or extramural) should be recorded, although this will almost always be submucosal (intramural) within local excision specimens. Lymphatic

channels lack the muscular wall evident in veins and usually, though not always, contain no red blood cells. Confidently identifying thin-walled submucosal vessels as lymphatic channels or post-capillary venules may be extremely difficult, and application of D2-40 immunohistochemistry in selected cases is recommended given this potentially important distinction (52). Immunohistochemistry may also help distinguish lymphatic and/or venous invasion from retraction artefact or tumour 'budding'. Lymphatic and/or venous invasion should only be recorded as positive if the features are considered definitive.

The significance of perineural invasion has only been demonstrated for CRC in surgical resection specimens not local resections. However for consistency the presence and deepest level (intramural (intramuscular or submucosal) or extramural) of perineural invasion should be reported for all CRC resection specimens (2).

6.8 Presence of a precursor lesion

Invasive carcinoma may destroy any precursor non-invasive lesion but, if any residual precursor is identified, the nature of this should be recorded. This will usually be a 'classical' adenoma, but may on occasion be some other polyp such as a SSL or TSA.

6.9 Margin assessment

Both peripheral (mucosal) and deep margins need to be assessed. The peripheral margin of a local excision may be involved by invasive carcinoma, by non-invasive adenoma, or clear of both. The precise measurement of the closest proximity of the deep margin from invasive tumour should be recorded.

Most large polyps detected in BCSP practice are removed by diathermy snare or similar devices. Diathermy resection produces a zone of diathermy burn which can be up to several millimetres thick. Due to coagulation of tissue, and this introduces a number of secondary artefactual changes (Figure 6A). These include:

- the diathermied plane of resection is drawn back into the stalk of the polyp and may be buried beneath the less affected mucosal rim
- coagulated blood vessels may stand proud of the rest of the retracted diathermy plane as they do not shrink to the same degree as the surrounding stroma
- possible marked clefting alongside the coagulated blood vessels because of the differential shrinkage of vessels and stroma - the coagulation zone is brittle and so may split or fragment during dissection
- the loose submucosal stroma may appear markedly disrupted beyond the zone of diathermy burn, probably due to a vaporisation effect

Care should be taken to take account of artefact which could give rise to a false assessment of distance of tumour to the margin. Drawing a straight line to join the two edges of the retracted plane and using that as a putative plane will give an erroneous measurement if either the tumour is close to the margin and also retracts back into the polyp, or the lesion is sessile but develops a curved shape due to diathermy and fixation. For this reason, it is advised that the outer edge of the diathermy zone is used for assessment of the margin (Figures 6B & 6C).

1. Starting from the muscularis mucosae on one side, draw a smooth line following the outer edge of the diathermy burn to run to the muscularis mucosae of the opposite side. Include any indentations, but ignore any artefactual splits and clefts.
2. Measure the distance of invasive carcinoma to the notional line. Distances should be recorded in millimetres to one decimal point.

Cancer in whatever context (for example in blood vessels or present as pools of mucinous carcinoma) should be considered when assessing tumour proximity to a margin. If there is coexisting epithelial misplacement care should be taken to ensure benign elements such as mucin lakes are not included. If there is infiltration by malignant glands into the diathermy zone and this is associated with morphological distortion of tissue to the extent that it is not possible to confidently identify tumour clearance from the outer margin (Figure 6D), then this should be regarded as margin involvement and a distance of 0mm of clearance recorded. Cytokeratin immunohistochemistry may help assessment in this situation by identifying neoplastic glands within the diathermy zone and their relationship with the outer edge of the zone of diathermy.

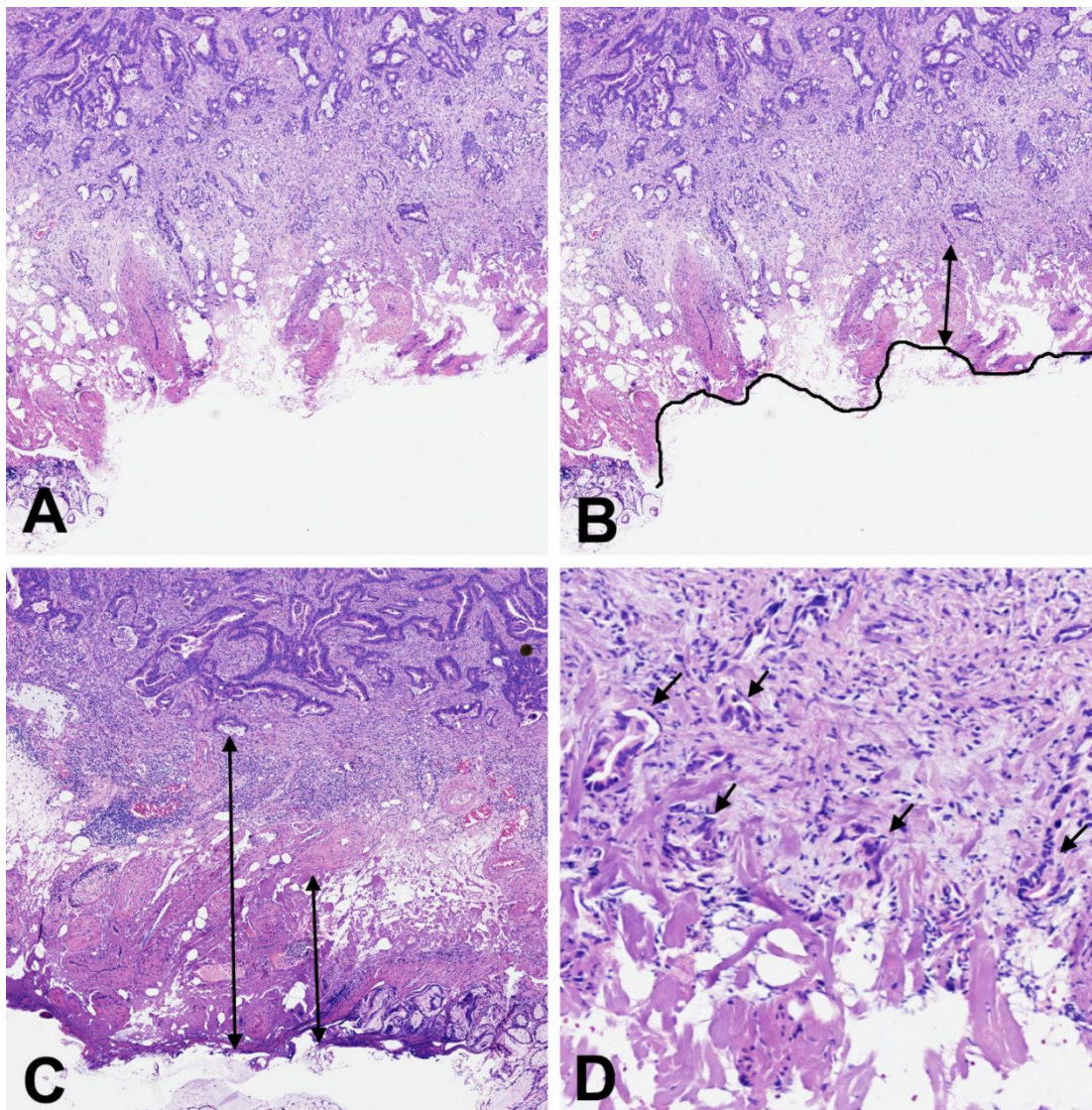


Figure 6: Diathermy artefact and margin assessment

Diathermy snare resection introduces a zone of secondary artefactual changes that makes margin assessment difficult.

A. Stromal vaporisation, clefting and withdrawal of the resection plane is most marked adjacent to thick submucosal blood vessels.

B. Measurement of tumour to resection margin should avoid such artefacts and a best attempt made to measure to the true resection margin (arrow). A distance of <1 mm from tumour to margin is considered margin involvement (R1 resection status).

C. The zone of diathermy artefact can be several millimetres thick depending on the excision technique employed (short arrow = 2.1 mm); tumour is well clear of the outer (true) resection margin here (long arrow = 3.9 mm). Measurement of clearance should not be to the inner aspect of the diathermy zone, in this event.

D. However, any infiltration by malignant glands into the diathermy zone (short arrows) is regarded as margin involvement (0 mm distance recorded), as it is not possible to confidently determine the true extent of infiltration in this situation.

Inking the diathermy line is not recommended because of the artefactual clefting and the disruption of loose connective tissue stroma within the polyp stalk, both of which can 'wick' marking ink for a considerable distance into the stalk. The zone of diathermy burn should provide adequate evidence of the true margin. Problems in assessment may also arise because the axis of section does not include the diathermy line or because of cross cut elements in convoluted lesions.

In general:

- when dissecting polyps ensure that the plane of section includes the diathermy line
- when assessing polyps be aware of their three-dimensional configuration and their orientation
- sections cut at deeper levels may assist assessment, particularly if the lesion is convoluted or the artefact is marked
- in cases of doubt adopt a conservative approach and only measure to a margin about which you are confident

Involvement of a peripheral margin may indicate the need for repeat endoscopy and further local excision. Involvement of the deep resection margin by invasive tumour has traditionally been an indication for considering surgical intervention. There has been considerable discussion and controversy in the literature over the degree of clearance that might be regarded as acceptable in tumours which extend close to the deep submucosal margin. Most existing guidance considers a clearance of <1 or 1 mm as needing consideration of further therapy (2, 3, 11). However there is recent evidence to suggest that for pT1 tumours only tumour present at the true or estimated resection margin, or within the diathermy burn zone, should be considered for further treatment. This may be local re-excision if no other adverse pathology features are identified (34,35,53). However it is considered that more substantive evidence is required before a change of protocol is made, and a margin of 1mm or less remains the indicator for incomplete excision until this is forthcoming.

If tumour is close to the excision margin, multiple levels (at least three and preferably more) should be examined in the assessment of possible margin involvement, with adjunctive immunohistochemistry if required. Careful follow-up of the local excision site of carcinomas less than 1mm from the margin is recommended if the MDT decide not to undertake a further excision or resection.

6.10 Tumour budding

There is considerable evidence emerging that identification of so-called 'tumour budding' in local excision specimens may predict outcome or indicate increased risk of nodal metastatic disease (35,36,54,55). However studies reporting the significance of

tumour budding employ a wide variety of methods of assessment, some requiring cytokeratin immunohistochemistry, and there remain concerns over methodologies, cut-offs and reproducibility given the wide ranges of budding reported in CRC (56). For these reasons, routine reporting of tumour budding is currently not recommended. International standards have been agreed (57) but these await validation in a screening context.

References

- 1 Schreuders EH, Ruco A, Rabeneck L, et al. Colorectal cancer screening: a global overview of existing programmes. *Gut* 2015;64:1637-49 doi:10.1136/gutjnl-2014-309086 (doi).
- 2 Loughrey MB, Quirke P, Shepherd NA. Standards and datasets for reporting cancers: Dataset for colorectal cancer histopathology reports. Version 4 London: Royal College of Pathologists 2017.
- 3 Quirke P, Risio M, Lambert R, et al. Quality assurance in pathology in colorectal cancer screening and diagnosis-European recommendations. *Virchows Arch* 2011;458:1-19 doi:10.1007/s00428-010-0977-6 (doi).
- 4 National Institute for Clinical Excellence. Molecular testing strategies for Lynch syndrome in people with colorectal cancer. 22 February 2017 <https://www.nice.org.uk/guidance/dg27> (accessed 16/12/2017)
- 5 Feakins RM, British Society of Gastroenterology. Inflammatory bowel disease biopsies: updated British Society of Gastroenterology reporting guidelines. *J Clin Pathol* 2013;66:1005-26 doi:10.1136/jclinpath-2013-201885 (doi).
- 6 Shepherd NA, Warren BF, Williams GT, et al. Morson & Dawson's Gastrointestinal Pathology. Oxford: Wiley-Blackwell 2013.
- 7 Cairns SR, Scholefield JH, Steele RJ, et al. Guidelines for colorectal cancer screening and surveillance in moderate and high risk groups (update from 2002). *Gut* 2010;59:666-89 doi:10.1136/gut.2009.179804 (doi).
- 8 Hamilton SR, Bosman FT, Boffetta P, et al. Carcinoma of the colon and rectum. In: Bosman FT, Carneiro F, Hruban RH, et al., eds. WHO classification of tumours of the digestive system. Lyon: IARC Press 2010.
- 9 Heitman SJ, Ronksley PE, Hilsden RJ, et al. Prevalence of adenomas and colorectal cancer in average risk individuals: a systematic review and meta-analysis. *Clin Gastroenterol Hepatol* 2009;7:1272-8 doi:10.1016/j.cgh.2009.05.032 (doi).
- 10 Eichenseer PJ, Dhanekula R, Jakate S, et al. Endoscopic mis-sizing of polyps changes colorectal cancer surveillance recommendations. *Dis Colon Rectum* 2013;56:315-21 doi:10.1097/DCR.0b013e31826dd138 (doi).
- 11 Williams JG, Pullan RD, Hill J, et al. Management of the malignant colorectal polyp: ACPGBI position statement. *Colorectal Dis* 2013;15 Suppl 2:1-38 doi:10.1111/codi.12262 (doi).
- 12 Taylor JL, Coleman HG, Gray RT, Kelly PJ, Cameron RI, O'Neill CJ, Shah RM, Owen TA, Dickey W, Loughrey MB A comparison of endoscopy versus pathology sizing of colorectal adenomas and potential implications for surveillance colonoscopy. *Gastrointest Endosc*. 2016 Aug;84(2):341-51.
- 13 Atkin WS, Morson BC, Cuzick J. Long-term risk of colorectal cancer after excision of rectosigmoid adenomas. *N Engl J Med* 1992;326:658-62 doi:10.1056/NEJM199203053261002 (doi).

- 14 Ishii T, Notohara K, Umapathy A, et al. Tubular adenomas with minor villous changes show molecular features characteristic of tubulovillous adenomas. *Am J Surg Pathol* 2011;35:212-20 doi:10.1097/PAS.0b013e318205df20 (doi).
- 15 Atkin WS, Edwards R, Kralj-Hans I, et al. Once-only flexible sigmoidoscopy screening in prevention of colorectal cancer: a multicentre randomised controlled trial. *Lancet* 2010;375:1624-33 doi:10.1016/S0140-6736(10)60551-X (doi).
- 16 Terry MB, Neugut AI, Bostick RM, et al. Reliability in the classification of advanced colorectal adenomas. *Cancer Epidemiol Biomarkers Prev* 2002;11:660-3.
- 17 Turner JK, Williams GT, Morgan M, et al. Interobserver agreement in the reporting of colorectal polyp pathology among bowel cancer screening pathologists in Wales. *Histopathology* 2013;62:916-24 doi:10.1111/his.12110 (doi).
- 18 Osmond A, Li-Chang H, Kirsch R, et al. Interobserver variability in assessing dysplasia and architecture in colorectal adenomas: a multicentre Canadian study. *J Clin Pathol* 2014;67:781-6 doi:jclinpath-2014-202177 (pii).
- 19 Konishi F, Morson BC. Pathology of colorectal adenomas: a colonoscopic survey. *J Clin Pathol* 1982;35:830-41.
- 20 Griggs RKS, Novelli MR, Sanders DSA, Warren BF, Williams GT, Quirke P, Shepherd NA. Challenging diagnostic issues in adenomatous polyps with epithelial misplacement in bowel cancer screening: five years' experience of the BCSP Expert Board. *Histopathology* 2017; 70: 466–472.
- 21 Loughrey MB, Shepherd NA. The pathology of bowel cancer screening. *Histopathology* 2015;66:66-77 doi:10.1111/his.12530 (doi).
- 22 Bateman AC, Shepherd NA. UK guidance for the pathological reporting of serrated lesions of the colorectum. *J Clin Pathol* 2015;68:585-91 doi:10.1136/jclinpath-2015-203016 (doi).
- 23 Snover DC, Ahnen DJ, Burt RW, et al. Serrated polyps of the colon and rectum and serrated polyposis. In: Bosman FT, Carneiro F, Hruban RH, et al., eds. WHO classification of tumours of the digestive system. Lyon: IARC Press 2010.
- 24 Bosman F, Carneiro F, Hruban R, et al., eds. WHO classification of Tumours of the Digestive System. Lyon: IARC Press 2010.
- 25 Carr NJ, Mahajan H, Tan KL, et al. Serrated and non-serrated polyps of the colorectum: their prevalence in an unselected case series and correlation of BRAF mutation analysis with the diagnosis of sessile serrated adenoma. *J Clin Pathol* 2009;62:516-8 doi:10.1136/jcp.2008.061960 (doi).
- 26 Bateman AC. Pathology of serrated colorectal lesions. *J Clin Pathol* 2014;67:865-74 doi:jclinpath-2014-202175 (pii).
- 27 Davis H, Irshad S, Bansal M, et al. Aberrant epithelial GREM1 expression initiates colonic tumorigenesis from cells outside the stem cell niche. *Nat Med* 2015;21:62-70 doi:10.1038/nm.3750 (doi). Mataka H, Matsui T,

28 Agaimy A, Stoehr R, Vieth M, Hartmann A. Benign serrated colorectal fibroblastic polyps/intramucosal perineuriomas are true mixed epithelial-stromal polyps (hybrid hyperplastic polyp/mucosal perineurioma) with frequent BRAF mutations. *Am J Surg Pathol* 2010; 34: 1663-71.

29 Pai R, Mojtahed A, Rouse R, Soetikno R, Kaltenbach T, Ma L, Arber D, Plesec T, Goldblum JR, Pai, R. Histologic and molecular analyses of colonic perineurial-like proliferations in serrated polyps: perineurial-like stromal proliferations are seen in sessile serrated adenomas. *Am J Surg Pathol* 2011; 35: 1373-80.

30 Groisman G, HersHKovitz D, Vieth, M, Sabo E. Colonic perineuriomas with and without crypt serration: a comparative study. *Am J Surg Pathol* 2013; 37: 745-51.

31 Yao T, et al. Long pedunculated colonic polyp composed of mucosa and submucosa: proposal of a new entity, colonic muco-submucosal elongated polyp. *Dis Colon Rectum* 1998;41:1557-61.

32 Nakamura S, Kino I, Akagi T. Inflammatory myoglandular polyps of the colon and rectum. A clinicopathological study of 32 pedunculated polyps, distinct from other types of polyps. *Am J Surg Pathol* 1992;16:772-9.

33 Xu F, Xu J, Lou Z, et al. Micropapillary component in colorectal carcinoma is associated with lymph node metastasis in T1 and T2 Stages and decreased survival time in TNM stages I and II. *Am J Surg Pathol* 2009;33:1287-92 doi:10.1097/PAS.0b013e3181a5387b (doi).

34 Brown IS, Bettington ML, Bettington A, et al. Adverse histological features in malignant colorectal polyps: a contemporary series of 239 cases. *J Clin Pathol* 2015 doi:jclinpath-2015-203203 (pii).

35 Ueno H, Mochizuki H, Hashiguchi Y, et al. Risk factors for an adverse outcome in early invasive colorectal carcinoma. *Gastroenterology* 2004;127:385-94 doi:S0016508504007176 (pii).

36 Egashira Y, Yoshida T, Hirata I, et al. Analysis of pathological risk factors for lymph node metastasis of submucosal invasive colon cancer. *Mod Pathol* 2004;17:503-11 doi:10.1038/modpathol.3800030.

37 Beaton C, Stephenson BM, Williams GL. Risk of lymph node metastasis in malignant colorectal polyps. *Colorectal Dis* 2014;16:67 doi:10.1111/codi.12404 (doi).

38 Bosch SL, Teerenstra S, de Wilt JH, et al. Predicting lymph node metastasis in pT1 colorectal cancer: a systematic review of risk factors providing rationale for therapy decisions. *Endoscopy* 2013;45:827-34 doi:10.1055/s-0033-1344238 (doi).

39 Halvorsen TB, Seim E. Degree of differentiation in colorectal adenocarcinomas: a multivariate analysis of the influence on survival. *J Clin Pathol* 1988;41:532-7.

40 Young J, Simms LA, Biden KG, et al. Features of colorectal cancers with high-level microsatellite instability occurring in familial and sporadic settings: parallel pathways of tumorigenesis. *Am J Pathol* 2001;159:2107-16 doi:10.1016/S0002-9440(10)63062-3.

41 Braun MS, Richman SD, Quirke P, et al. Predictive biomarkers of chemotherapy efficacy in colorectal cancer: results from the UK MRC FOCUS trial. *J Clin Oncol* 2008;26:2690-8 doi:10.1200/JCO.2007.15.5580; 10.1200/JCO.2007.15.5580.

42 Hutchins G, Southward K, Handley K, et al. Value of mismatch repair, KRAS, and BRAF mutations in predicting recurrence and benefits from chemotherapy in colorectal cancer. *J Clin Oncol* 2011;29:1261-70 doi:10.1200/JCO.2010.30.1366 (doi).

43 Kikuchi R, Takano M, Takagi K, et al. Management of early invasive colorectal cancer. Risk of recurrence and clinical guidelines. *Dis Colon Rectum* 1995;38:1286-95.

44 Nascimbeni R, Burgart LJ, Nivatvongs S, et al. Risk of lymph node metastasis in T1 carcinoma of the colon and rectum. *Dis Colon Rectum* 2002;45:200-6.

45 Haggitt RC, Glotzbach RE, Soffer EE, et al. Prognostic factors in colorectal carcinomas arising in adenomas: implications for lesions removed by endoscopic polypectomy. *Gastroenterology* 1985;89:328-36.

46 Ueno H, Mochizuki H, Hashiguchi Y, et al. Risk factors for an adverse outcome in early invasive colorectal carcinoma. *Gastroenterology* 2004;127:385-94.

47 Watanabe T, Itabashi M, Shimada Y, et al. Japanese Society for Cancer of the Colon and Rectum (JSCCR) guidelines 2010 for the treatment of colorectal cancer. *Int J Clin Oncol* 2012;17:1-29 doi:10.1007/s10147-011-0315-2 (doi).

48 Barresi V, Reggiani Bonetti L, Vitarelli E, et al. Immunohistochemical assessment of lymphovascular invasion in stage I colorectal carcinoma: prognostic relevance and correlation with nodal micrometastases. *Am J Surg Pathol* 2012;36:66-72 doi:10.1097/PAS.0b013e31822d3008; 10.1097/PAS.0b013e31822d3008.

49 Ishii M, Ota M, Saito S, et al. Lymphatic vessel invasion detected by monoclonal antibody D2-40 as a predictor of lymph node metastasis in T1 colorectal cancer. *Int J Colorectal Dis* 2009;24:1069-74 doi:10.1007/s00384-009-0699-x; 10.1007/s00384-009-0699-x.

50 Talbot IC, Ritchie S, Leighton M, et al. Invasion of veins by carcinoma of rectum: method of detection, histological features and significance. *Histopathology* 1981;5:141-63.

51 Roxburgh CS, McMillan DC, Anderson JH, et al. Elastica staining for venous invasion results in superior prediction of cancer-specific survival in colorectal cancer. *Ann Surg* 2010;252:989-97 doi:10.1097/SLA.0b013e3181f1c60d; 10.1097/SLA.0b013e3181f1c60d.

52 Ervine AJ, McBride HA, Kelly PJ, et al. Double immunohistochemistry enhances detection of lymphatic and venous invasion in early-stage colorectal cancer. *Virchows Arch* 2015;467:265-71 doi:10.1007/s00428-015-1792-x (doi).

53 Gill MD, Rutter MD, Holtham SJ. Management and short-term outcome of malignant colorectal polyps in the north of England(1). *Colorectal Dis* 2013;15:169-76 doi:10.1111/j.1463-1318.2012.03130.x (doi).

54 Ishikawa Y, Akishima-Fukasawa Y, Ito K, et al. Histopathologic determinants of regional lymph node metastasis in early colorectal cancer. *Cancer* 2008;112:924-33 doi:10.1002/cncr.23248; 10.1002/cncr.23248.

55 Wang LM, Kevans D, Mulcahy H, et al. Tumor budding is a strong and reproducible prognostic marker in T3N0 colorectal cancer. *Am J Surg Pathol* 2009;33:134-41 doi:10.1097/PAS.0b013e318184cd55; 10.1097/PAS.0b013e318184cd55.

56 Graham RP, Vierkant RA, Tillmans LS, et al. Tumor Budding in Colorectal Carcinoma: Confirmation of Prognostic Significance and Histologic Cutoff in a Population-based Cohort. *Am J Surg Pathol* 2015;39:1340-6 doi:10.1097/PAS.0000000000000504 (doi).

57 Lugli A, Kirsch R, Ajioka Y, Bosman F, Cathomas G, Dawson H, El Zimaity H, Fléjou JF, Hansen TP, Hartmann A, Kakar S, Langner C, Nagtegaal I, Puppa G, Riddell R, Ristimäki A, Sheahan K, Smyrk T, Sugihara K, Terris B, Ueno H, Vieth M, Zlobec I, Quirke P. Recommendations for reporting tumor budding in colorectal cancer based on the International Tumor Budding Consensus Conference (ITBCC) 2016. *Mod Pathol*. 2017;30:1299-1311.

58 Brierley JD, Gospodarowicz MK, Wittekind C (eds). UICC, Union for International Cancer Control, *TNM Classification of Malignant Tumours (8th edition)*. Oxford, UK: Wiley-Blackwell, 2017.

Appendix 1

Bowel Cancer Screening System (BCSS) polyp dataset (2017)

Polyp type: Adenoma	Subtype: Tubular adenoma Tubulovillous adenoma Villous adenoma
Serrated lesion	Subtype: Hyperplastic polyp Sessile serrated lesion Sessile serrated lesion with dysplasia Traditional serrated adenoma Mixed polyp
Inflammatory polyp Peutz-Jeghers polyp Juvenile polyp Other polyp	Subtype: Neuroendocrine tumour (carcinoid) Lymphoid polyp Lipoma Stromal Other polyp
Normal mucosa	
Polyp margin clear:	Yes No
Polyp size (mm):	
Polyp dysplasia:	Low grade High grade Not applicable
Polyp carcinoma:	Yes No

Appendix 2

Recommended SNOMED codes

The assistance in compiling this section of Dr. Brian Rous, Addenbrookes Hospital, Cambridge, is gratefully acknowledged.

Topography (T) codes are used in the Systemised Nomenclature of Medicine (SNOMED) to indicate the site of lesions, Morphology (M) codes are used to indicate the morphological diagnosis and disease (D) codes may also be applicable. Additional procedure (P) codes can be used either to indicate the screening origin of the specimen, or the endoscopic/surgical procedure involved. Codes commonly applied in the setting of bowel cancer screening are given below, although the list is not exhaustive. Some diagnoses, according to current nomenclature, do not have a corresponding SNOMED codes in any of the SNOMED versions in current use e.g. serrated lesions, and the nearest identifiable code has been selected. Pathologists are encouraged to use SNOMED codes providing the greatest level of detail possible e.g. specifying the precise anatomical site (T code) of any lesion within the colon, or using the M code for 'mucinous adenocarcinoma' when applicable, rather than that for 'adenocarcinoma'.

Note that licensing has been withdrawn for versions of SNOMED earlier than SNOMED CT and therefore migration to SNOMED CT is recommended. SNOMED CT codes are likely to evolve and users are encouraged to ensure the codes utilised are up to date whenever this system is implemented.

	SNOMED II	SNOMED 3.5/RT	SNOMED CT (ConceptID)
General			<i>Procedure</i>
Screening specimen	P2-06000	P2-06000	20135006
Site			<i>Body structure</i>
Caecum	T-67100	T-59100	32713005
Ascending colon	T-67200	T-59420	9040008
Hepatic (right colic) flexure	T-67300	T-59438	48338005
Splenic (left colic) flexure	T-67500	T-59442	72592005
Transverse colon	T-67400	T-59440	485005
Descending colon	T-67600	T-59460	32622004
Sigmoid colon	T-67700	T-59470	60184004
Rectum	T-68000	T-59600	34402009
Colon, not otherwise specified	T-67000	T-59300	71854001
Diagnosis			<i>Finding</i>
Specimen inadequate	M-09010	M-09010	112631006
Normal	M-00100	M-00100	30389008

	SNOMED II	SNOMED 3.5/RT	SNOMED CT (ConceptID)
Polyps			<i>Morphologic abnormality</i>
Tubular adenoma	M-82110	M-82110	19665009
Tubulovillous adenoma	M-82630	M-82630	61722000
Villous adenoma	M-82611	M-82611	128859003
Hyperplastic polyp	M-72042	M-72042	62047007
Sessile serrated lesion	M-76801	M-76801	103679000
Traditional serrated adenoma	M-82130	M-82130	128653004
Inflammatory polyp	M-76820	M-76820	76235005
Mucosal prolapse	M-31050	M-31050	29696001
Juvenile polyp	M-75662	M-75662	110448004
Neuroendocrine tumour (carcinoid)	M-82403	M-82403	81622000
Leiomyoma	M-88900	M-88900	44598004
Schwannoma	M-95600	M-95600	985004
Neurofibroma	M-95400	M-95400	89084002
Ganglioneuroma	M-94900	M-94900	53801007
Gastrointestinal stromal tumour	M-89361	M-89361	128755003
Lipoma	M-88500	M-88500	46720004

Cancers			<i>Morphologic abnormality</i>
Adenocarcinoma	M-81403	M-81403	35917007
Adenocarcinoma within a polyp	M-82103	M-82103	43233001
Suspicious of adenocarcinoma	M-67060	M-67060	44085002
Mucinous adenocarcinoma	M-84803	M-84803	72495009
Signet ring cell adenocarcinoma	M-84903	M-84903	87737001
Adenosquamous carcinoma	M-85603	M-85603	59367005
Squamous cell carcinoma	M-80703	M-80703	28899001
Neuroendocrine carcinoma	M-82463	M-82463	55937004
Small cell carcinoma	M-80413	M-80413	74364000
Goblet cell carcinoid tumour	M-82433	M-82433	31396002
Mixed adenocarcinoma-neuroendocrine carcinoma (MANEC)	M-82443	M-82443	51465000
Undifferentiated carcinoma	M-80203	M-80203	38549000
Carcinoma, other	M-80103	M-80103	68453008

	SNOMED II	SNOMED 3.5/RT	SNOMED CT (ConceptID)
Dysplasia grade			<i>Morphologic abnormality</i>
Low grade dysplasia	M-74001	M-74001	43185009
High grade dysplasia	M-74003	M-74003	55237006
Other pathology			<i>Disorder</i>
Ulcerative colitis	D5-41110	D5-41110	64766004
Crohn's disease	D5-41000	D5-41000	34000006
Chronic idiopathic inflammatory bowel disease, unclassified	D5-409A0	D5-409A0	359664009
Inflammation, unspecified	M-40000	M-40000	23583003

Appendix 3

TNM 8 classification of colorectal tumours

- pT Primary tumour
- pTX Primary tumour cannot be assessed
- pT0 No evidence of primary tumour
- pT1 Tumour invades submucosa
- pT2 Tumour invades muscularis propria
- pT3 Tumour invades into subserosa or into non-peritonealised pericolic or perirectal tissues
- pT4 Tumour perforates visceral peritoneum (4a) and /or directly invades other organs or structures (4b)
- pN Regional lymph nodes
- pNX Regional lymph nodes cannot be assessed
- pN0 No regional lymph node metastatic disease
- pN1 Metastatic disease in 1 to 3 regional lymph nodes
- pN1a Metastasis in 1 regional lymph node
 - pN1b Metastases in 2 to 3 regional lymph nodes
 - pN1c Tumour deposit(s), i.e. satellites,* in the subserosa, or in non-peritonealised pericolic or perirectal soft tissue *without* regional lymph node metastatic disease
- pN2 Metastatic disease in 4 or more regional lymph nodes
- pN2a Metastases in 4–6 regional lymph nodes
 - pN2b Metastases in 7 or more regional lymph nodes
- pM Distant metastatic disease
- pM1 Distant metastatic disease
- pM1a Metastasis confined to one organ without peritoneal metastases
 - pM1b Metastases in more than one organ
 - pM1c Metastases to the peritoneum with or without other organ involvement

*Tumour deposits or satellites are discrete macroscopic or microscopic nodules of cancer in the pericolorectal adipose tissue's lymph drainage area of a primary carcinoma that are discontinuous from the primary and without histological evidence of residual lymph node or identifiable vascular or neural structures.